Immediate Postoperative Reversal of Disc Herniation Following Facetal Distraction-Fixation Surgery: Report of 4 Cases

Atul Goel, Abhidha Shah, Neeraj Patni, Raghvendra Ramdasi

■ BACKGROUND: **We report cases of 4 patients where Goel facet distraction surgery resulted in restoration of herniated disc back into the intervertebral disc space in the immediate postoperative period. Such a fate of herniated disc has not been recorded earlier.**

■ METHODS: **During the period 2010 to 2011, 4 patients with single level 'contained' herniated disc that extended to the posterior surface of adjoining vertebral bodies and resulted in severe cord and root compression were surgically treated. The posterior longitudinal ligament was essentially intact in all 4 cases. Surgery involved facetal distraction technique using Goel facet spacers as a standalone method of treatment.**

■ RESULTS: **Immediate postoperative imaging showed nearly complete disappearance of the disc bulge, restoration of the cervical cord girth and distraction-fixation arthrodesis of the spinal segment. All patients had remarkable and sustained clinical improvement. At a 5-year follow-up, all 4 patients were well and showed no evidence of recurrent symptoms or recurrence of herniated disc-related imaging findings.**

■ CONCLUSIONS: **The indications for facetal distraction surgery, its mechanisms of action and its suitability in the presented cases are discussed.**

INTRODUCTION

In 2010, we described the possibility of use of facet distraction-fixation in the treatment of degenerative diseases of the spine in general and cervical spondylotic disease in particular.[1-4] The technique involves impaction of Goel facet spacers within the distracted facet joints on both sides. Distraction of the facets resulted in reversal of a number of pathological events that are related to spondylotic disease. We report a series of 4 cases wherein a large part of the disc herniation was restored into the confines of the disc space, an event that was confirmed by investigations in the immediate postoperative period and after a minimum follow-up of 5 years. Disc restoration resulted in decompression of the cord and root and remarkable and sustained clinical recovery. Such a fate of the herniated part of the disc has not been reported earlier. The success in the reported cases consolidates our belief that facet distraction-fixation technique reverses the spondylotic changes in the spine circumventing the need of direct handling of any part of the bone, ligament, osteophyte, or disc.

METHODS

Four patients, aged 37, 45, 46, and 51 years, were treated in our department in 2010–2011. Written and oral informed consent were obtained from all patients. There were 3 males and 1 female. Findings of the clinical examination at the time of admission and essential parameters on imaging are summarized in **Table 1** (**Figures 1–3**) All 4 patients had a large, single-level disc herniation that extended onto the posterior surface of adjoining vertebral bodies. In all cases, the posterior longitudinal ligament appeared intact, as suggested by its apparent superior and inferior continuity and by the smooth margin of the posterior disc bulge.

Surgery

The essential steps of surgery have been described previously[1,4] and are summarized here. The patient was placed prone with the head end of the operating table elevated by 30 degrees. Gardner-Wells traction was applied to stabilize the head during surgery, and the direction of the traction resulted in a near-floating head position and avoided pressure on the face.

A midline skin incision was made. The spinous process of the axis was exposed to identify the exact level of surgery. The facets on both sides were exposed by a subperiosteal dissection. The

Key Words
- Cervical spondylosis
- Facet distraction-arthrodesis
- Goel facet spacer
- Intervertebral disc

Department of Neurosurgery, King Edward VII Memorial Hospital and Seth G.S. Medical College, Parel, Mumbai, India

To whom correspondence should be addressed: Atul Goel, M.Ch. [E-mail: atulgoel62@hotmail.com]

Citation: World Neurosurg. (2016) 94:339-344.
http://dx.doi.org/10.1016/j.wneu.2016.07.020

*Journal homepage: **www.WORLDNEUROSURGERY.org***

*Available online: **www.sciencedirect.com***

Table 1. Clinical and Radiologic Parameters

Patient	Sex	Age, Years	Symptoms	Level of Involvement	Preop VAS Score	Preop JOA Score	Level(s) Distracted	Postop VAS Score	Postop JOA Score
1	F	51	Neck pain, spasticity, left-sided limb weakness	C4-5	8	9	C3-4, C4-5, and C5-6	2	14
2	M	37	Tingling, numbness, and weakness of all 4 limbs	C3-4	4	8	C3-4 and C4-5	2	12
3	M	46	Neck pain, right lower limb weakness	Atlanto-occipital assimilation, C2-3 fusion with C3-4 PID	8	15	C3-4 and C4-5	1	17
4	M	45	Neck pain, weakness of all 4 limbs	C4-5	7	11	C3-4, C4-5, and C5-6	2	15

VAS, visual analog scale (0, no pain to 10, maximum pain); JOA, Japanese Orthopedic Association score; PID, prolapsed intervertebral disc; Preop, preoperative; Postop, postoperative

physical appearance of the facets and the articulation was evaluated and correlated with imaging findings to determine the extent of fixation required.

The number of levels requiring fixation was assessed based on the evidence of facetal instability observed during the operation. More than 1 level of fixation was done in all cases despite the fact that disc herniation was observed essentially at 1 level. The number of levels fixed depended on direct inspection and manual manipulation of the facets to assess their stability. The facets at these levels were distracted using osteotomes ranging in size from 1.5 mm to 4 mm. The flat end of the osteotome was introduced into the facet joint and then turned 90 degrees to make it vertical to effect distraction. The articular cartilage was widely removed using a screwing motion of the osteotome. A Goel cervical facet spacer was then inserted into the joint by gentle hammering over the base of the spacer impactor. The spacers were 8 mm in diameter and either 2.5 or 3 mm in height.

The interspinous ligaments were widely removed in the treated spinal segments. A bone graft was harvested from the iliac crest and then placed over the adequately prepared host bone area of laminae, facets, and spinous processes. In addition, small pieces were forced into the region of the joint adjoining the spacer. Postoperatively, the traction was discontinued, and the patient was placed in a 4-poster hard cervical collar for a 3-month period.

Routine postoperative investigation on the day after surgery (at approximately 18 hours postsurgery) showed significant migration of the herniated portion of the disc back within the confines of the disc space. A cerebrospinal fluid signal could now be observed anterior to the cord at the affected level in at least 2 cases. The cord girth was restored to near normalcy (**Figures 1–3**). The changes in intervertebral bone measurements after the surgery are elaborated in **Table 2**.

Fusion of the spinal segments was defined as the absence of motion and alterations in the interspinous process, interlaminar body, and intervertebral body distances on flexion-extension radiographs obtained at a 3-month follow-up. Based on this criterion, successful fusion was obtained at all treated spinal levels. The visual analog scale and Japanese Orthopedic Association scores were recorded at 3 months, 6 months, 1 year, and 2 years. The scores recorded at 2 years are shown in **Table 1**. All patients remained essentially symptom-free at a minimum follow-up of 5 years. Bone fusion could be clearly observed in the treated vertebral segments.

DISCUSSION

Various approaches to treating intervertebral disc herniation have been proposed and therapeutically adopted[5-9]; however, it seems that the last word in this treatment remains to be determined. For centuries, traction has been used as a therapeutic modality for degenerative spinal problems. The effectiveness of this form of treatment can be gauged from its lasting popularity and clinical success. There have been anecdotal reports of reversal of disc herniation following traction.[10-12] Facetal distraction surgery that aims to achieve segmental arthrodesis, as proposed by us, results in sustained traction and fixation of the spinal segment in a distracted position. We have shown that facetal distraction can result in reversal of several pathological events related to spondylotic disease.

Owing to the oblique bone profile of the facets, their distraction produces a circumferential increase in intervertebral height. The procedure results in an increase in spinal canal and root canal dimensions by distracting the boundaries of the bony canal and stretching of the "buckled" ligaments. The disc height is increased, likely resulting in restoration of its water content. Accordingly, facet distraction-arthrodesis is a reliable alternative form of treatment of single- or multiple-level degenerative spondylotic disease—related radiculopathy or myelopathy.[4,5] In 2011, we reported our satisfactory clinical experience with this form of treatment. Our ongoing study in this area involves analysis of the indications for this treatment approach in patients with kyphotic spinal deformity associated with degenerative spinal disease.

In the case scenario presented here, anterior cervical discoidectomy is a rather straightforward operation and would have been the obvious choice. The familiarity of most surgeons with the anterior cervical discoidectomy and fusion technique in anterior cervical disc surgery and the ease of surgery with the patient in the supine position are additional advantages. However, contained disc herniation, or the disc bulge seen in the presence of an intact posterior longitudinal ligament, probably made the case suitable

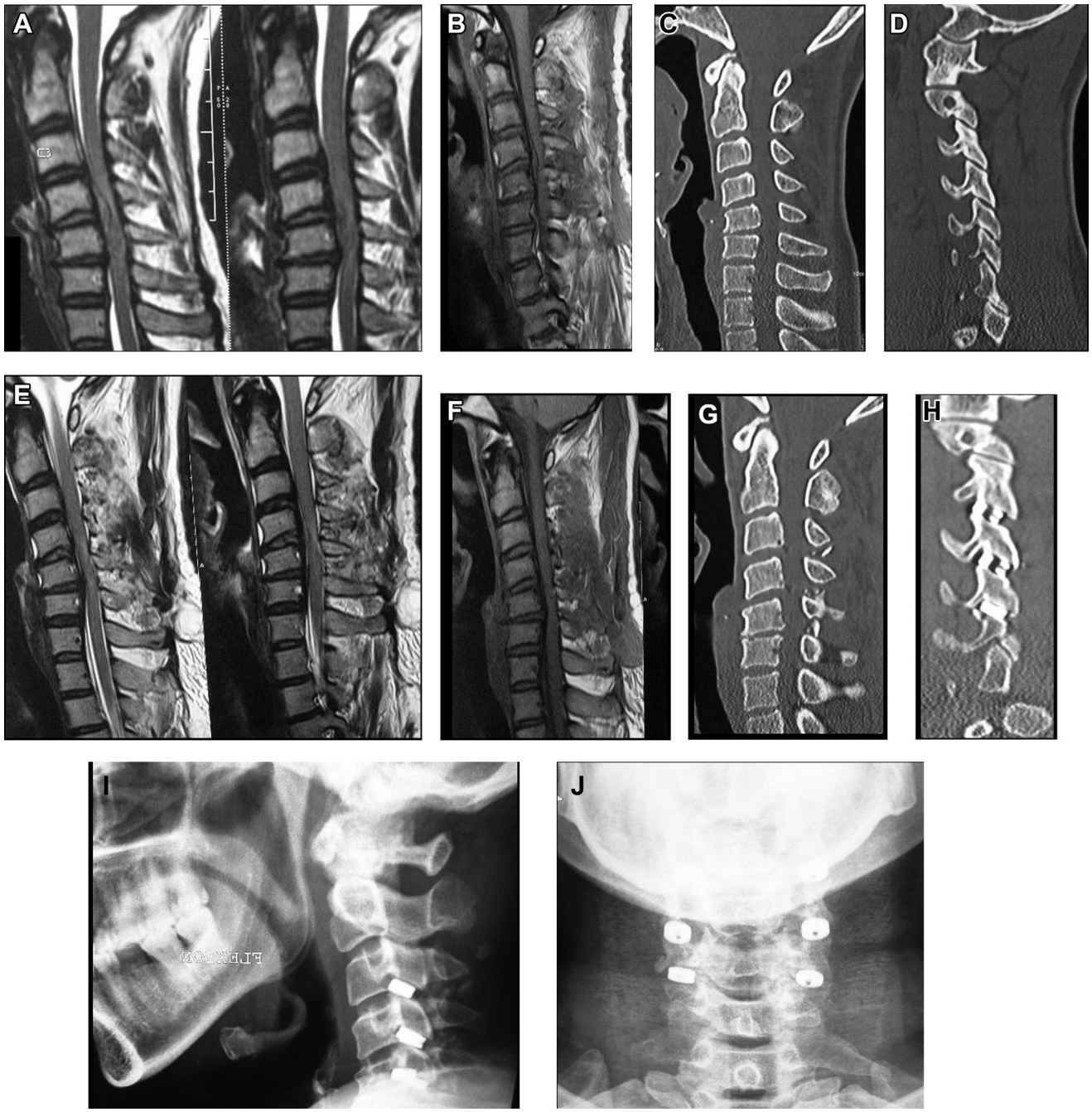

Figure 1. Images of a 51-year-old female patient. (**A**) T2-weighted magnetic resonance imaging (MRI) image, sagittal cut, showing the herniated disc at C4-5. Evidence of continuity of the posterior longitudinal ligament can be seen, as can evidence of compression of the cord adjoining the C5-6 level. (**B**) T1-weighted MRI image showing the herniated disc. (**C**) Computed tomogtraphy (CT) scan showing a loss of cervical lordosis. (**D**) Sagittal cut of CT scan traversing through the facets. (**E**) T2-weighted MRI image showing disappearance of the C4-5 disc and evidence of its restoration back into the disc space, which now appears enlarged. (**F**) T1-weighted MRI image showing disappearance of the disc. (**G**) CT scan showing enlargement of the C4-5 and C5-6 disc spaces. (**H**) CT scan showing spacers within the facets at the C3-4, C4-5, and C5-6 levels. (**I**) Lateral radiograph showing the spacers within the facet joints. (**J**) Anteroposterior radiograph showing the spacers.

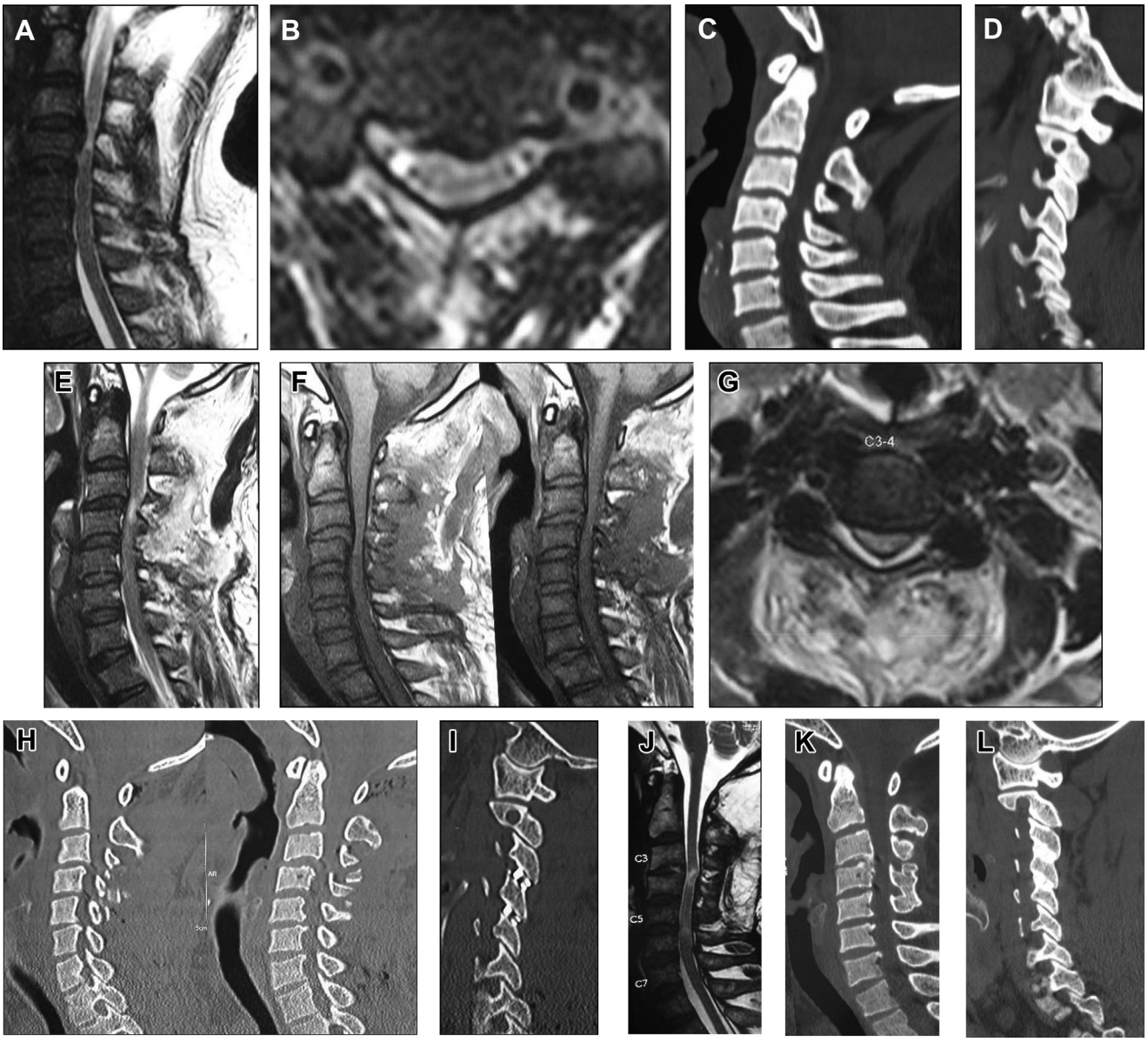

Figure 2. Images of a 37-year-old male patient. (**A**) T2-weighted sagittal magnetic resonance imaging (MRI) showing the C3-4 level herniated disc and related cord compression, with evidence of continuity of the posterior longitudinal ligament. (**B**) Axial images showing the disc herniation. (**C**) Computed tomography (CT) scan showing evidence of disc space reduction at multiple spinal levels. (**D**) Sagittal cut of CT through the facets. (**E**) T2-weighted MRI showing complete restoration of the disc back into the disc space, but with persistent myelomalacia of the cord. (**F**) T1-weigthed MRI showing restoration of the disc and enlargement of the disc spaces. (**G**) Axial image showing reversal of disc herniation. (**H**) CT scan showing enlargement of the disc spaces and widening of the interlaminar spaces. (**I**) CT scan showing the spacers within the facets of C3-4 and C4-5. (**J**) T2-weighted MRI 50 months after surgery showing no evidence of recurrent disc herniation. (**K**) Sagittal image of CT scan showing fusion of C4-5 vertebrae. (**L**) Sagittal image of CT scan showing fusion of C3-4 and C4-5 facets.

for facetal distraction surgery. In our earlier experience, we observed that our facet-distraction surgery stretched the buckled ligaments. This feature was obvious in the cases discussed herein, where the herniated disc was clearly pushed back into the disc space, likely by the restored stretchability of the posterior longitudinal ligament. However, considering this issue, cases involving disc extrusion with herniation beyond the confines of the posterior longitudinal ligament might not be suitable for treatment by the facetal distraction technique proposed here. This technique is indicated in cases where "vertical" facetal instability

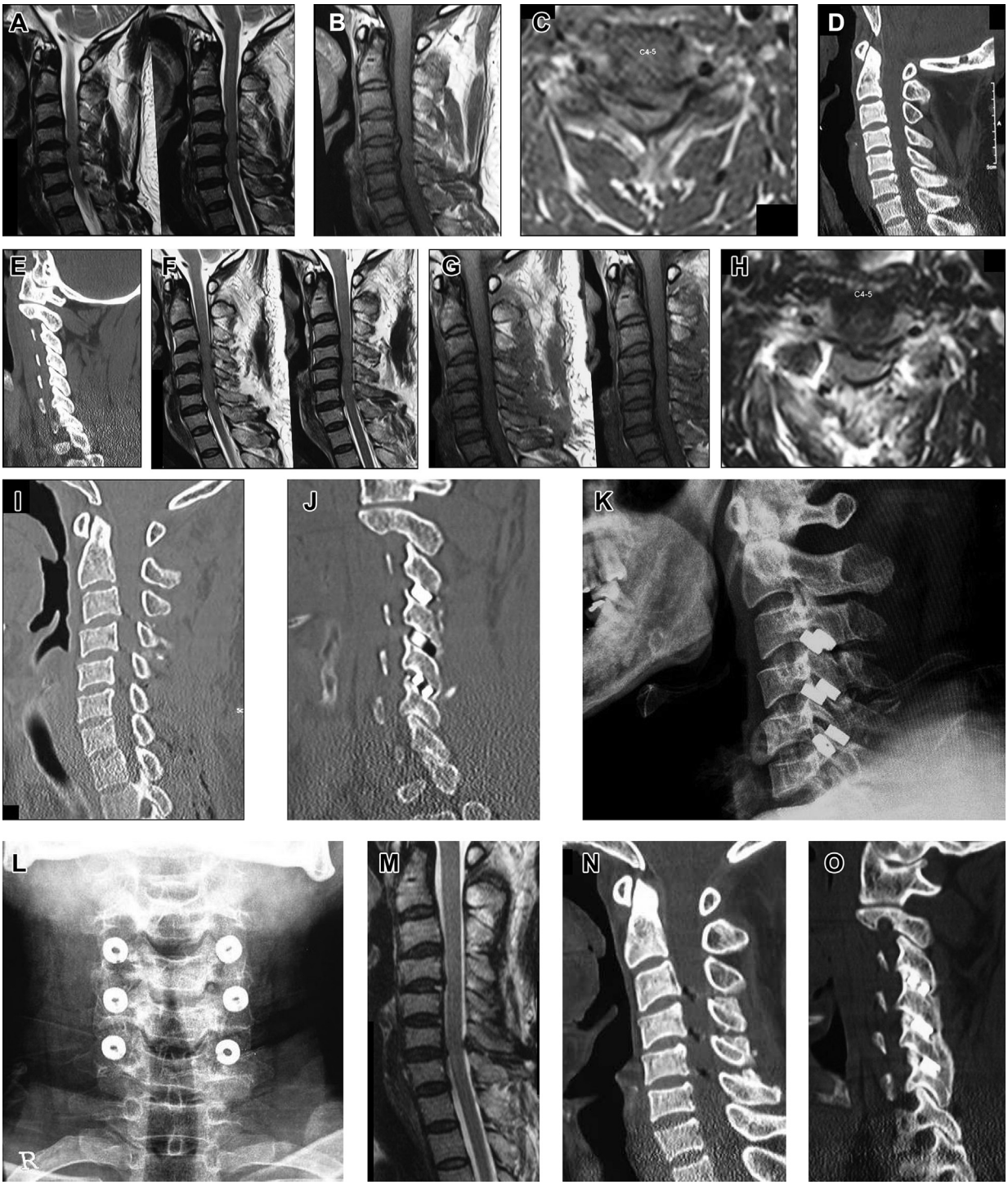

Figure 3. Images of a 45-year-old male patient. (**A**) Sagittal T2-weighted magnetic resonance imaging (MRI) showing the C4-5 level disc protrusion. (**B**) Sagittal T1-weighted MRI showing the herniated disc and an intact posterior longitudinal ligament. (**C**) Axial scan showing the herniated disc. (**D**) Preoperative computed tomography (CT) scan, sagittal image through the facets. (**E**) Preoperative CT scan with sagittal cut passing through the facets. (**F**) Postoperative T2-weighted MRI showing restoration of the herniated disc and an increase in the disc space height. (**G**) T1-weighted MRI showing restoration of the disc in the disc space. (**H**) Axial image showing the reduction in herniated disc size. (**I**) CT scan showing the increase in height of the disc space. (**J**) Postoperative CT scan showing spacers within the C3-4, C4-5, and C5-6 levels. (**K**) Lateral X-ray showing spacers within the facets. (**L**) Anteroposterior X-ray showing the spacers. (**M**) T2-weighted MRI done 36 months after surgery showing no evidence of recurrent disc herniation. (**N**) CT scan, sagittal image, showing evidence of midline bone fusion between the C3 and C6 levels. (**O**) Sagittal image through the facets showing fusion between C3 and C6 vertebral levels.

Table 2. Radiologic Data

	Pre-Operative Range (Mean)	Post-Operative Range (Mean)	Increase (Mean)
Facetal height	2—2.5 mm (2.35 mm)	4.5—5 mm (4.8 mm)	2.5 mm
Foraminal height	5—7 mm (6.5 mm)	7—9.5 mm (8.92 mm)	2.3 mm
Interspinous height	2.5—5 mm (3.9 mm)	5—7 mm (6.2 mm)	2.3 mm
Disc space height			
Anterior	1.5—3.5 mm (2.9 mm)	3—5 mm (4 mm)	1.1 mm
Middle	2—4 mm (3.3 mm)	4—5 mm (4.5 mm)	1.2 mm
Posterior	2—4 mm (3.4 mm)	4—5 mm (4.7 mm)	1.3 mm

or telescoping of the facets is considered the primary pathogenetic factor. The safe, firm, and secure stabilization at the fulcrum of cervical spinal movements provides a ground for segmental spinal stability.[13,14]

In all of the cases in the present series, facetal distraction and fixation were done at more than 1 level, even when the disc protrusion was obvious at only 1 intervertebral level. The decision to perform fusion of adjoining articulations was made during surgery after direct observation of joint status. Identification of an unstable spinal segment was based essentially on our extensive experience in handling the craniovertebral junction and subaxial spinal facets. Although neuromonitoring with the patients in a prone surgical position is likely necessary, this was not done in the present series. Retrolisthesis of the facets has been suggested to be secondary to a reduced intervertebral disc space height; however, it appears that the reduction in facetal height and its retrolisthesis may be secondary to neck musculature weakness. The fact that distraction of the facets results in restoration of the several pathological features and degenerative changes in the spine suggests that facetal instability might be the primary feature in the pathogenesis of spondylosis, rather than disc degeneration or reduced disk water content, as has been generally accepted.[1-4] The proposed surgical approach ultimately results in arthrodesis of the spinal segment. Placement of bone graft within the joint cavity and over the laminae after removal of all intervertebral ligaments and appropriate preparation of host bone aided the arthrodesis.

We recommend the use of a cervical collar for 3 months after surgery. Most surgeons treating similar cases with anterior cervical discoidectomy and fusion do not find the need for such external arthrodesis after surgery. Given that motion-preserving options are currently under intense evaluation, the feasibility of preserving motion and providing sustained facetal distraction should be evaluated.

REFERENCES

1. Goel A, Shah A. Facetal distraction as treatment for single- and multilevel cervical spondylotic radiculopathy and myelopathy: a preliminary report. *J Neurosurg Spine*. 2011;14:689-696.

2. Goel A. Facet distraction-arthrodesis technique: can it revolutionize spinal stabilization methods? *J Craniovertebr Junction Spine*. 2011;2:1-2.

3. Goel A. Facet distraction spacers for treatment of degenerative disease of the spine: rationale and an alternative hypothesis of spinal degeneration. *J Craniovertebr Junction Spine*. 2010;1:65-66.

4. Goel A, Shah A, Jadhav M, Nama S. Distraction of facets with intraarticular spacers as treatment for lumbar canal stenosis: report on a preliminary experience with 21 cases. *J Neurosurg Spine*. 2013;19:672-677.

5. Cardoso MJ, Rosner MK. Multilevel cervical arthroplasty with artificial disc replacement. *Neurosurg Focus*. 2010;28:E19.

6. Cloward RB. The anterior approach for removal of ruptured cervical discs. *J Neurosurg*. 1958;15:602-617.

7. Faldini C, Leonetti D, Nanni M, Di Martino A, Denaro L, Denaro V, et al. Cervical disc herniation and cervical spondylosis surgically treated by Cloward procedure: a 10-year-minimum follow-up study. *J Orthop Trauma*. 2010;11:99-103.

8. Lafuente J, Casey AT, Petzold A, Brew S. The Bryan cervical disc prosthesis as an alternative to arthrodesis in the treatment of cervical spondylosis: 46 consecutive cases. *J Bone Joint Surg Br*. 2005;87:508-512.

9. Narotam PK, Pauley SM, McGinn GJ. Titanium mesh cages for cervical spine stabilization after corpectomy: a clinical and radiological study. *J Neurosurg*. 2003;99(2 Suppl):172-180.

10. Ozturk B, Gunduz OH, Ozoran K, Bostanoglu S. Effect of continuous lumbar traction on the size of herniated disc material in lumbar disc herniation. *Rheumatol Int*. 2006;26:622-626.

11. Onel D, Tuzlaci M, Sari H, Demir K. Computed tomographic investigation of the effect of traction on lumbar disc herniations. *Spine (Phila Pa 1976)*. 1989;14:82-90.

12. Sari H, Akarirmak U, Karacan I, Akman H. Computed tomographic evaluation of lumbar spinal structures during traction. *Physiother Theory Pract*. 2005;21:3-11.

13. Shah A. Morphometric analysis of the cervical facets and the feasibility, safety and effectiveness of Goel inter-facet spacer distraction technique. *J Craniovertebr Junction Spine*. 2014;5:9-14.

14. Satoskar SR, Goel AA, Mehta PH, Goel A. Quantitative morphometric analysis of the lumbar vertebral facets and evaluation of feasibility of lumbar spinal nerve root and spinal canal decompression using the Goel intraarticular facetal spacer distraction technique: a lumbar/cervical facet comparison. *J Craniovertebr Junction Spine*. 2014;5:157-162.

Conflict of interest statement: The authors declare that the article content was composed in the absence of any commercial or financial relationships that could be construed as a potential conflict of interest.

Received 23 April 2016; accepted 6 July 2016

Citation: World Neurosurg. (2016) 94:339-344.
http://dx.doi.org/10.1016/j.wneu.2016.07.020

*Journal homepage: **www.WORLDNEUROSURGERY.org***

*Available online: **www.sciencedirect.com***