

CASE REPORT

Sylvian fissure epidermoid cyst presenting with intention tremor

Abhidha Shah, Fedaa Makkiyah, Atul Goel

Department of Neurosurgery, K.E.M. Hospital and Seth G.S. Medical College, Mumbai, Maharashtra, India

ABSTRACT

Epidermoid tumors are benign tumors which contain keratin, cellular debris, and cholesterol, and are lined with stratified squamous epithelium. They grow in discreet silence sustained over a multitude of years. The tumors most commonly present with headache and seizures. We report the case of a 24-year-old male with a large sylvian fissure epidermoid tumor who presented with intention tremor. The patient was operated, and a near-total excision of the tumor was performed with a resolution of the tremor.

Key words: Epidermoid, intention tremor, middle fossa

Introduction

Epidermoid tumors comprise about 0.2–1% of all primary intracranial tumors. These tumors are commonly located in the cerebellopontine angle, in the cisterns around the tentorium and in the suprasellar and parasellar cisterns.^[1,2] Occasionally, these lesions occur in the Meckel's cave, in the middle fossa, diploe of bone, and in the spinal canal.^[1-3] Symptoms are usually related to the position of the cyst. The most frequent symptoms are headache and seizures.^[1] Uncommonly, they may present with chemical meningitis or psychosis. We present a 24-year-old man with a sylvian fissure epidermoid cyst with an extension into the parasellar region and the crural cistern who presented with intention tremor. Our literature search revealed only one similar case of a middle fossa epidermoid tumor presenting with a rubral tremor.^[4]

Case Report

A right-handed 24-year-old gentleman presented to us with gradually increasing intention tremor of his left sided

limbs for the last 2 years. Over the last 1-month, the tremor had significantly worsened and affected his daily routine. He also complained of a mild headache. His neurological examination was normal except for the tremor. The tremor was low amplitude, course tremor which affected the upper extremities more than the lower extremities. The tremor began after initiating any movement and stopped at rest. The proximal muscles were more involved than the distal muscles. Magnetic resonance imaging (MRI) of the brain showed an irregular lesion in the right sylvian fissure with extensions in the frontal and temporal opercula, the parasellar region and the crural cistern. The lesion was hypointense on T1-weighted imaging, hyperintense on T2-weighted imaging with no enhancement on contrast. The lesion showed restricted diffusion [Figure 1]. There was encasement of the middle cerebral artery and displacement of the posterior communicating artery. There was compression seen on the right cerebral peduncle. A diagnosis of sylvian fissure epidermoid tumor was made, and the patient was operated. A right frontotemporal craniotomy was performed and the dura was opened based on the sphenoid ridge. The sylvian fissure was splayed open by the pearly white epidermoid tumor. A tumor debulking was begun. The tumor had encased the middle cerebral artery and its branches and extended via the crural cistern into the middle fossa. A near-total

Access this article online	
Quick Response Code:	Website: www.asianjns.org
	DOI: 10.4103/1793-5482.175620

Address for correspondence:

Dr. Abhidha Shah, Department of Neurosurgery, K.E.M. Hospital and Seth G.S. Medical College, Parel, Mumbai - 400 012, Maharashtra, India.
E-mail: abhidha@gmail.com

This is an open access article distributed under the terms of the Creative Commons Attribution-NonCommercial-ShareAlike 3.0 License, which allows others to remix, tweak, and build upon the work non-commercially, as long as the author is credited and the new creations are licensed under the identical terms.

For reprints contact: reprints@medknow.com

How to cite this article: Shah A, Makkiyah F, Goel A. Sylvian fissure epidermoid cyst presenting with intention tremor. *Asian J Neurosurg* 2016;11:174-5.

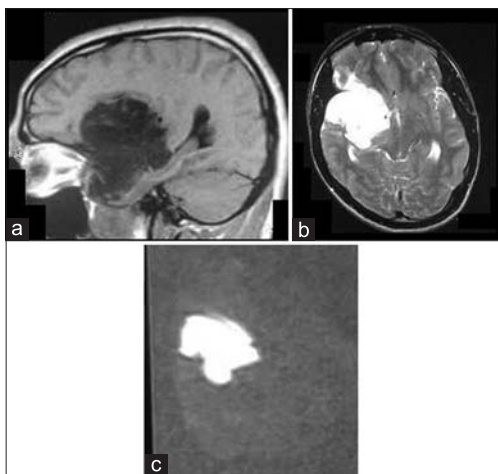


Figure 1: Preoperative images of a 24-year-old male with right sylvian fissure epidermoid cyst. (a) Sagittal T1-weighted image showing the hypointense lesion in the sylvian fissure. (b) Axial T2-weighted image showing the hyperintense epidermoid with compression of the midbrain. (c) Diffusion-weighted image showing the restriction

excision of the tumor was performed with only a small bit stuck to the middle cerebral artery being left behind. At the end of the surgery, a panoramic view of the internal carotid artery, anterior cerebral artery, middle cerebral artery and, the posterior communicating artery was obtained. The second and the third cranial nerves were identified and safeguarded. The patient was well following the surgery. In the immediate postoperative period, the intention tremor decreased in intensity and over a period of 3 months completely disappeared. At a follow-up of 1-year, the patient is well and is back to all his routine activities. Histopathology of the tumor revealed the characteristic features of epidermoid tumor. Postoperative MRI showed a complete excision of the tumor [Figure 2].

Discussion

Epidermoid tumors are characterized by a slow growth rate, relatively large size and a varied extension at the time of presentation. The tumor is known for its potential to open up anatomical spaces in the region of its occurrence and its propensity for encasement of major arteries and perforators. Due to their slow growth, they develop a symbiotic relation with the brain and do not cause many neurological deficits.^[5] The most common presentation of epidermoid tumors is headache and seizures.^[1] Occasionally, cerebellopontine angle epidermoid tumors can present with trigeminal neuralgia and tic convulsif.^[6]

Intention tumors may be an occasional presenting feature of posterior fossa tumors. Thalamic tumors, thalamomesencephalic cavernomas, ependymal cysts have been known to present with parkinsonian or Holmes tremor.^[7] Krauss *et al.* reported 12 patients with a tremor in a series of 225 patients with astrocytomas of the thalamus or basal

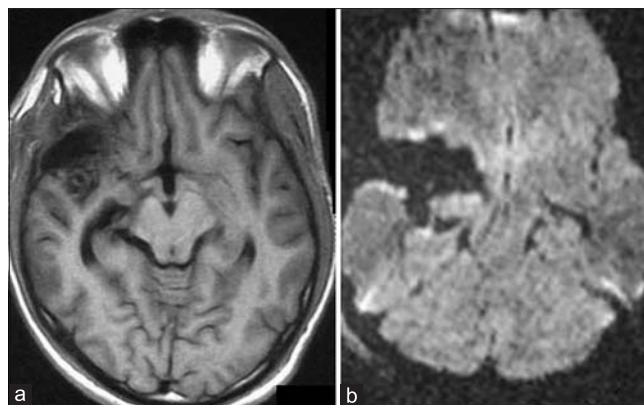


Figure 2: Postoperative images. (a) Axial T1-weighted image showing excision of the epidermoid with no compression on the midbrain. (b) Diffusion-weighted image showing excision of the epidermoid

ganglia.^[8] We report a case of a sylvian fissure epidermoid cyst presenting with intention tremor. Menon *et al.* have reported a case of a giant middle fossa epidermoid presenting with Holmes tremor. We could not find any other case of epidermoid tumor in the literature with this unique presentation.^[4]

Intention tremor, Holmes tremor, and resting tremor are the types of tumors usually found in association with central nervous system tumors. Intention tremor is defined as a tremor that appears during target-directed movements. The tremor increases in amplitude as the hand approaches the target and is not present at rest. Cerebellar tumors or lesions that disrupt the cerebellar outflow tracts usually cause this kind of tremor. Holmes tremor or rubral tremor is usually unilateral, has a low frequency, is present at rest and also has postural and action components. However, it usually disappears during sleep.

Two different neural pathways have been hypothesized to be responsible for Holmes tremor.^[9,10] One pathway involves the nigrostriatal dopaminergic fibers. The dopaminergic denervation of the striatum could be responsible for the resting component of the Holmes tremor. The other pathway involved in the genesis of Holmes tremor is the dentato-rubro-thalamic tract. Axons of neurons in the dentate nucleus travel through the superior cerebellar peduncle and cross the midline to the opposite side at the level of the midbrain in the decussation of the superior cerebellar peduncle. From here some fibers end in the red nucleus and most of the fibers end by synapsing with cells in the contralateral ventrolateral nucleus of the thalamus. The axons from the thalamus further terminate in the primary motor area of the cerebral cortex. This is also the cerebellar outflow tract. Interruption of this pathway explains the intention component of the Holmes tremor.

Our patient had a large sylvian fissure epidermoid tumor with extension into the parasellar region and the crural cistern. This crural component caused compression of the ipsilateral midbrain with compression of the cerebellar outflow tract. This led to the intention tremor in the left sided limbs. There was no

damage to the dopaminergic pathway as this was an extrinsic lesion, thus explaining the lack of the resting component. After excision of the tumor, the tremor initially decreased in intensity and later completely disappeared.

Conclusion

Tremor can be a rare presenting feature of intracranial lesions. Removal of the lesion causes resolution of the tremor.

Financial support and sponsorship

Nil.

Conflicts of interest

There are no conflicts of interest.

References

1. Goel A, Muzumdar D, Desai K. Anterior tentorium-based epidermoid tumours: Results of radical surgical treatment in 96 cases. *Br J Neurosurg* 2006;20:139-45.
2. Desai KI, Nadkarni TD, Fattepurkar SC, Goel AH. Pineal epidermoid cysts: A study of 24 cases. *Surg Neurol* 2006;65:124-9.
3. Nadkarni T, Dindorkar K, Muzumdar D, Goel A. Epidermoid tumor within Meckel's cave – Case report. *Neurol Med Chir (Tokyo)* 2000;40:74-6.
4. Menon B, Sasikala P, Agrawal A. Giant middle fossa epidermoid presenting as holmes' tremor syndrome. *J Mov Disord* 2014;7:22-4.
5. Kothari M, Goel A. The heuristics of craniospinal epidermoid tumors. *Neurol India* 2006;54:143.
6. Son DW, Choi CH, Cha SH. Epidermoid tumors in the cerebellopontine angle presenting with trigeminal neuralgia. *J Korean Neurosurg Soc* 2010;47:271-7.
7. Bhatoe HS. Movement disorders caused by brain tumours. *Neurol India* 1999;47:40-2.
8. Krauss JK, Nobbe F, Wakhloo AK, Mohadjer M, Vach W, Munding F. Movement disorders in astrocytomas of the basal ganglia and the thalamus. *J Neurol Neurosurg Psychiatry* 1992;55:1162-7.
9. Bain PG. The management of tremor. *J Neurol Neurosurg Psychiatry* 2002;72 Suppl 1:13-19.
10. Berkovic SF, Bladin PF. Rubral tremor: Clinical features and treatment of three cases. *Clin Exp Neurol* 1984;20:119-28.

