**J Neurosurg Spine 14:**689–696, 2011

# Facetal distraction as treatment for single- and multilevel cervical spondylotic radiculopathy and myelopathy: a preliminary report

## Technical note

**Atul Goel, M.Ch., and Abhidha Shah, M.Ch.**

*Department of Neurosurgery, King Edward VII Memorial Hospital and Seth G.S. Medical College, Parel, Mumbai, India*

The authors discuss their successful preliminary experience with 36 cases of cervical spondylotic disease by performing facetal distraction using specially designed Goel cervical facet spacers. The clinical and radiological results of treatment are analyzed. The mechanism of action of the proposed spacers and the rationale for their use are evaluated.

Between 2006 and February 2010, 36 patients were treated using the proposed technique. Of these patients, 18 had multilevel and 18 had single-level cervical spondylotic radiculopathy and/or myelopathy. The average follow-up period was 17 months with a minimum of 6 months. The Japanese Orthopaedic Association classification system, visual analog scale (neck pain and radiculopathy), and Odom criteria were used to monitor the clinical status of the patient. The patients were prospectively analyzed. The technique of surgery involved wide opening of the facet joints, denuding of articular cartilage, distraction of facets, and forced impaction of Goel cervical facet spacers into the articular cavity. Additionally, the interspinous process ligaments were resected, and corticocancellous bone graft from the iliac crest was placed and was stabilized over the adjoining laminae and facets after adequately preparing the host bone. Eighteen patients underwent single-level, 6 patients underwent 2-level, and 12 patients underwent 3-level treatment. The alterations in the physical architecture of spine and canal dimensions were evaluated before and after the placement of intrafacet joint spacers and after at least 6 months of follow-up.

All patients had varying degrees of relief from symptoms of pain, radiculopathy, and myelopathy. Analysis of radiological features suggested that the distraction of facets with the spacers resulted in an increase in the intervertebral foraminal dimension (mean 2.2 mm), an increase in the height of the intervertebral disc space (range 0.4–1.2 mm), and an increase in the interspinous distance (mean 2.2 mm). The circumferential distraction resulted in reduction in the buckling of the posterior longitudinal ligament and ligamentum flavum. The procedure ultimately resulted in segmental bone fusion. No patient worsened after treatment. There was no noticeable implant malfunction. During the follow-up period, all patients had evidence of segmental bone fusion. No patient underwent reexploration or further surgery of the neck.

Distraction of the facets of the cervical vertebra can lead to remarkable and immediate stabilization-fixation of the spinal segment and increase in space for the spinal cord and roots. The procedure results in reversal of several pathological events related to spondylotic disease. The safe, firm, and secure stabilization at the fulcrum of cervical spinal movements provided a ground for segmental spinal arthrodesis. The immediate postoperative improvement and lasting recovery from symptoms suggest the validity of the procedure. *(DOI: 10.3171/2011.2.SPINE10601)*

**Key Words** • **cervical spondylosis** • **Goel cervical facet spacer** • **prolapsed intervertebral disc** • **osteophytes**

Cervical spondylosis is a common pathological entity, the treatment of which has evolved over the past century. The basic aim of treatment is decompression of the neural structures. More recently, fixation of the affected spinal segment has been advocated,[5,6,18,20,24] and motion-preserving options are currently under intense evaluation.[3,4,17,19,29]

A number of techniques have been used for spinal fixation.[5,6,18,20,24] We report a novel method of cervical spinal fixation using the technique of facetal distraction and fixation. Decompression of the neural structures was achieved by the technique without removal of any part of the disc, bone, or ligaments. The indications, mechanism of action, surgical technique, and the clinical outcomes

*Abbreviations used in this paper:* JOA = Japanese Orthopaedic Association; PLL = posterior longitudinal ligament; VAS = visual analog scale.

This article contains some figures that are displayed in color online but in black and white in the print edition.

are discussed on the basis of our surgical experience with 36 cases. The anatomical subtleties of the facets and joints and their suitability for the insertion of the proposed spacers are discussed.

## Methods

Between 2006 and February 2010, 36 patients with cervical spondylotic disease were treated using the proposed technique. Written informed consent was obtained from all patients. These patients were analyzed prospectively, and all patients underwent surgery performed by the first author (A.G.). The indication for the procedure was characteristic cervical spondylotic disease manifested by secondary canal stenosis. Patients had progressive neurological symptoms, bowel or bladder alterations, and failure of nonoperative management. Patients with an acute disc herniation or with an extruded disc were not included in the study. Patients with ossification of the PLL, posttraumatic injuries, associated infective and tumorous pathology, and rheumatoid disease were excluded. Patients exhibiting instability on dynamic images and those with clear evidence of intervertebral body fusions were not considered suitable for the proposed technique. We avoided our technique in patients with kyphotic deformity because in general we have favored anterior spondylectomy and fusion to maintain kyphosis-reduced alignment in such cases.

There were 20 men and 16 women whose ages ranged from 39 to 69 years (mean 51 years). Six patients had only radiculopathy, and 30 patients had varying extents of myelopathy. Eighteen patients underwent single-level, 6 patients underwent 2-level, and 12 patients underwent 3-level treatment. The presenting clinical symptoms, radiological features, and outcomes are listed in Tables 1–5. The JOA score,[7] VAS score,[15] and Odom criteria[21] were used to evaluate the patients before and after surgery and at follow-up lasting at least 6 months. All patients were evaluated using static and dynamic cervical spine radiography, CT scanning, and MR imaging. Static neutral lateral radiographs were used to assess cervical sagittal balance, whereas anteroposterior radiographs were used to exclude preoperative abnormal coronal alignment. All radiographic measurements were obtained with the neck in neutral position. The radiographic analyses that were performed included measurement of maximum intervertebral foraminal height, facet height, and interspinous process height. The intervertebral disc space height was measured at 3 levels: the anterior limit, midpoint, and posterior limit of the vertebral bodies (Table 5). The cervical lordotic angle was measured using neutral sagittal CT scanning. A line was drawn parallel to the inferior endplate of C-7, and another line was drawn through the midpoint of the anterior and posterior tubercles of C-1. Lines perpendicular to these lines were drawn until they intersected. The angle thus formed was the cervical lordotic angle.[28]

## Operative Technique

The patient was placed prone with the head end of the operating table elevated by 30°. Gardner-Wells traction was applied to stabilize the head during surgery, and the direction of the traction resulted in a near-floating head position and avoided pressure on the face. A midline skin incision was made. The spinous process of the axis was exposed in all cases to identify the exact level of surgery. The facets on both sides were exposed after a subperiosteal dissection. The physical appearance of the facet was evaluated. Facets with excessive movements and near-open joint cavity were considered unstable. These findings were valuable and were correlated with clinical symptoms and findings on images when considering the levels and extent of fixation. The facets were distracted using varying-sized osteotomes ranging from 1.5 to 4 mm in thickness. The flat end of the osteotome was introduced into the facet joint and then turned 90° to make it vertical to effect distraction. The articular cartilage was widely removed using a screwing motion of the osteotome and when necessary a power-driven microdrill. With the osteotome in place at the lateral edge of the joint, the Goel cervical facet spacer was impacted into the joint by using gentle hammering over the base of the spacer impactor (Fig. 1). The spacers varied in height from 2 to 4 mm, and the diameter was 8 mm. More often, spacers with a height of 2.5–3 mm were used. The impactor

**TABLE 1: Presenting clinical and radiological features in 36 patients who underwent facetal distraction**

| Parameter | Value* |
|---|---|
| sex | |
| male | 20 |
| female | 16 |
| median age (yrs) | 51 (range 39–69) |
| symptoms | |
| only radiculopathy | 6 |
| only myelopathy | 6 |
| radiculopathy & myelopathy | 24 |
| level of involvement | |
| C3–4 | 12 |
| C4–5 | 18 |
| C5–6 | 30 |
| C6–7 | 6 |
| no. of levels distracted | |
| 1 | 18 |
| 2 | 6 |
| 3 | 12 |

* Unless indicated otherwise, values represent the number of patients.

**TABLE 2: Grading of myelopathy according to JOA score**

| JOA Score | No. of Patients | |
|---|---|---|
| | Preop | 6 Mos Postop |
| <7 | 5 | 0 |
| 8–12 | 9 | 9 |
| >13 | 16 | 15 |
| 16–17 | 6 | 12 |

**TABLE 3: Grading according to the VAS***

| Type of Pain | Mean VAS Score (range) | | |
|---|---|---|---|
| | Preop | 3 Mos Postop | 6 Mos Postop |
| neck | 7.3 (4–8) | 2.1 (0–3) | 0.6 ( 0–1) |
| radicular | 8.1 (5–9) | 2.0 (0–4) | 0.4 (0–1) |

* A score of 0 represents no pain, and a score of 10 represents maximum pain.

held the spacer firmly by its screw-thread design, directed the course, and also restrained the spacer and prevented it from traveling beyond the joint confines (Fig. 1 right). A "give-way" feeling while impacting signaled complete insertion of the spacer within the joint. The interspinous ligaments were widely removed in the treated spinal segments. Bone graft was harvested from the iliac crest and was placed over the adequately prepared host bone area of laminae, facets, and spinous processes. Postoperatively, the traction was discontinued, and the patient was placed in a four-poster hard cervical collar for a period of 3 months, and all physical activities involving the neck were restricted during that period. However, sitting and standing were encouraged, given that during these maneuvers the weight of the head may assist in further impaction of the spacers. After this period and after confirmation of spinal fusion, all routine activities were permitted.

## Results

The follow-up period ranged from 6 to 37 months (mean 17 months). At latest follow-up, each patient underwent a complete evaluation. Neurological and radiographic assessments were performed by observers independent of the principal surgeon. The second author (A.S.) supervised the follow-up assessments. All patients underwent anteroposterior and lateral flexion and extension cervical spine radiography, MR imaging, and CT scanning. The evaluation included the location and degree of preoperative and postoperative pain using the VAS, subjective and objective alteration in sensation and weakness, walking difficulty, and bowel or bladder changes. The clinical outcome of surgery is elaborated in Tables 2–4. Student t-tests were used to compare the preoperative neurological status with the follow-up assessment at least 6 months after surgery by using the JOA scoring system. A p value $< 0.05$ indicated a statistically significant difference. All radiological measurements were made using calipers. The changes in the dimensions of the intervertebral spaces are listed in Table 5. On MR imaging, there was a clear reduction in the posterior disc bulge and ligamentum flavum indentation into the spinal canal, resulting in an overall increase in the spinal canal dimensions (Figs. 2–4). The measurements of the cervical lordotic angle are listed in Table 6. During the follow-up period, the operation was not repeated in any patient and no additional surgical procedures were performed at the same surgical level or at any other cervical spinal level. Fusion of the spinal segment was defined as the absence of motion and alterations in the interspinous process and interlaminar and intervertebral body distances on flexion-extension radiographs obtained at a follow-up of at least 6 months. Based on this criterion, successful fusion was obtained in all treated spinal levels. There was no implant-related complication or implant displacement when compared with the immediate postoperative situation in any case. There were no infections.

**TABLE 4: Outcome according to Odom criteria**

| Outcome | No. of Patients (%) |
|---|---|
| excellent | 25 (70) |
| good | 8 (22) |
| fair | 3 (8) |
| poor | 0 (0) |

**Fig. 1.** Photographs of the implant. **Left:** The various-sized spacers. The flat surface has serrations to make the surface rough. The hole with serrations is seen on the side of the implant, which is meant for the spacer holder. The hole in the center of the flat surface is meant to assist in arthrodesis. **Right:** The implant holder with the spacer.

## Discussion

Traction of the neck has been used over the past century in the management of spondylotic disease. The effectiveness of such a treatment method can be gauged by its lasting popularity and clinical success. Our preliminary observations suggest that distraction of the facets by manual implantation of metal spacers within the articular cavity results in sustained traction and fixation of the spinal segment and provides an opportunity for local arthrodesis.

The anatomical subtleties, significance of the oblique anatomical profile of the facets, and the overall movements that occur in facet joints have been discussed in the literature.[1,22,26] The firm consistency and mechanical strength of the facets and the pedicles has only infrequently been therapeutically used. A number of techniques using fixation of the facets with screws have been described in the literature.[2,14,26] The proximity of the facets to the nerve roots, vertebral artery, and spinal cord and the possible danger to these structures during screw implantation into the facets and into the relatively thin and obliquely angled pedicles are probably the reasons that these techniques have not been universally accepted or popularly used.

Increasing life expectancy has made spinal stenosis a common pathology in the elderly. Decrease in the intervertebral height is the hallmark of age-related loss of fluid within the disc space. It appears that instability of the spinal segment may play a crucial role in the pre-

**TABLE 5: Radiological parameters regarding the dimensions of the intervertebral spaces**

| Measurement | Value (mm)* | | |
|---|---|---|---|
| | Preop Range (mean) | Postop Range (mean) | Mean Increase |
| facetal height | 3.16 (2–4) | 4.5–6.5 (5.66) | 2.5 |
| foraminal height | 15.10 (10-18) | 17.30 (13-20) | 2.2 |
| interspinous height | 3.40 (1.5–4) | 5.40 (3.5–6) | 2.0 |
| disc space height | | | |
| anterior | 3.02 (1–3.5) | 3.41 (1.5–4) | 0.4 |
| middle | 3.63 (2–5) | 4.70 (3–6) | 1.1 |
| posterior | 2.73 (1–4) | 3.75 (2–5) | 1.2 |

* Values are presented as the means with ranges in parentheses.

senting clinical scenario and the observed radiological features. Reduction in disc space height, buckling of the PLL, buckling of the ligamentum flavum, reduction in the diameter of the spinal canal and root canal, and retrolisthesis of the facets occur simultaneously in such a situation. It appears that subtle instability of the spinal segment may be paramount in the pathogenesis of the entire structural deformation. Such instability is rather easily observed on direct visualization of the joint during surgery, even when preoperative dynamic radiographs do not depict such an event. Our experience with arthritis of the craniovertebral junction and with direct exposure of the atlantoaxial joint cavity over 23 years suggests that there is clear evidence of arthritis and instability of the facets in these cases.[8–13] Although not considered in the present evaluation, a decrease in height and retrolisthesis of

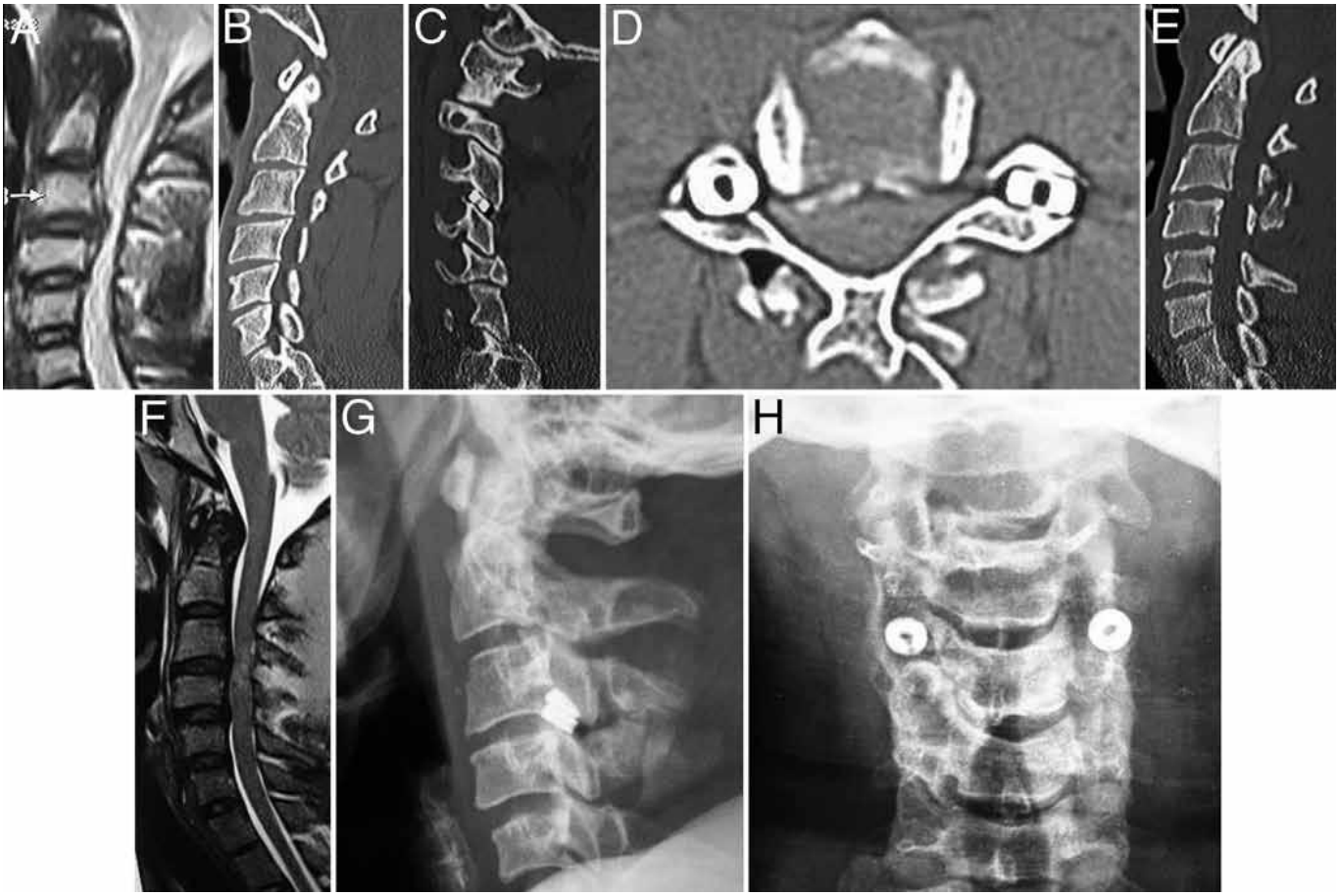


**Fig. 2.** Images obtained in a 39-year-old man. **A and B:** Preoperative images. Sagittal T2-weighted MR image showing cord compression opposite the C3–4 disc space **(A)**. Sagittal CT scan showing the reduced disc spaces **(B)**. **C–H:** Postoperative images. Sagittal CT scan showing the spacer within the C3–4 facet joint **(C)**. Axial CT scan showing the spacer in the joint **(D)**. Sagittal CT scan showing an increase in intervertebral space between C-3 and C-4 **(E)**. Sagittal MR image showing the increase in spinal canal size and reduction in the extent of cord compression **(F)**. Lateral radiograph showing the spacers in the joint **(G)**. Anteroposterior radiograph showing the spacers **(H)**.

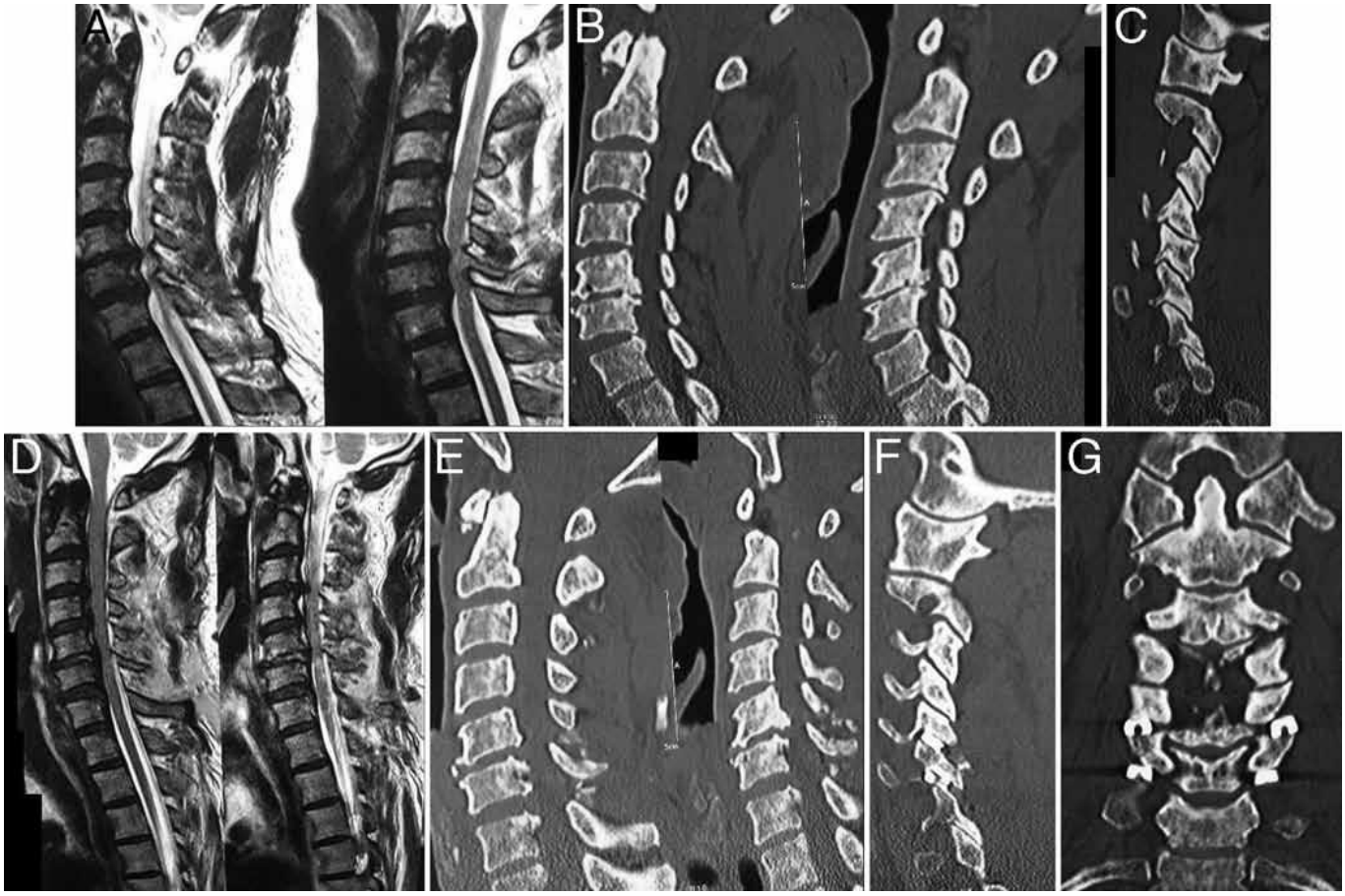


**Fig. 3.** Images obtained in a 68-year-old woman. The patient presented with complaints of neck and radicular pain and quadriparesis. **A–C:** Preoperative images. Sagittal T2-weighted MR images showing evidence of cord compression opposite the C5–6 and C6–7 disc levels **(A)**. Buckling of both PLLs and ligamentum flavum can be seen. Sagittal CT scans showing degenerative changes, more predominantly at the C5–6 level **(B)**. Sagittal CT scan showing the facets **(C)**. Degenerative changes can be appreciated at the C5–6 level. **D–G:** Postoperative images. Sagittal MR images showing increase in the canal size, reduction in the extent of cord compression, reduction in the posterior buckling of the PLL, and anterior buckling of the ligamentum flavum **(D)**. Sagittal CT scans showing an increase in the intervertebral and interspinous process spaces at the C5–6 and C6–7 levels **(E)**. Evidence of bone fusion can be seen between spinous processes. Sagittal CT scan showing spacers within the facets of C5–6 and C6–7 **(F)**. Coronal view showing the spacers **(G)**.

the facets are indicators of instability and can determine the need for distraction surgery. The general consensus favors the theory that the degenerative process initiated in the disc results in reduction of the disc space height, posterior osteophyte formation, and retrolisthesis of the facets. Decrease in interfacet height and retrolisthesis can result in a reduction in intervertebral canal height that can cause radiculopathy symptoms. It appears that this retrolisthesis is a result of potential or manifest instability of the segment. Dynamic images do not clearly demonstrate the instability of the facets because of their oblique profile and the difficulty in directly imaging the joints. It may be possible that the spondylotic disease process actually begins with facet instability and the discs are involved secondarily. The reversal of pathological events following facetal distraction provides support to such a hypothesis.

The oblique profile, relatively large size, firmness, and biomechanical strength of the facets and pedicles can be used effectively and safely for distraction of the spinal segments and fixation.[2,14,26] Distraction of the facets was done by surgically implanting specially designed spacers. Impaction of spacers in the facets caused several structural changes, resulting in reversal of the pathological effects of cervical spondylosis. Stability of the treated spinal segment, increase in interlaminar and interspinous process distances, and restoration of buckled ligaments of the region were obvious after the distraction of the facets. The results of MR imaging demonstrated that insertion of the spacer resulted in an increase in spinal canal diameter. The exit space of the nerve root was remarkably enlarged, as evident by an increase in height of the intervertebral foramen (Table 5). The process resulted in an increase in the intervertebral disc space and interspinous process height that resulted in reduction of the buckling of the PLL and ligamentum flavum (Figs. 2–4).

Goel cervical facet spacers were specially designed for the present study and are not yet commercially available. The spacers are made of medical-grade titanium metal. The spikes on both sides of the spacers assist in fixation of the implant. The spacer has multiple holes that allow bone arthrodesis. The rounded edge of the spacer avoids any inadvertent injury to the adjoining structure.

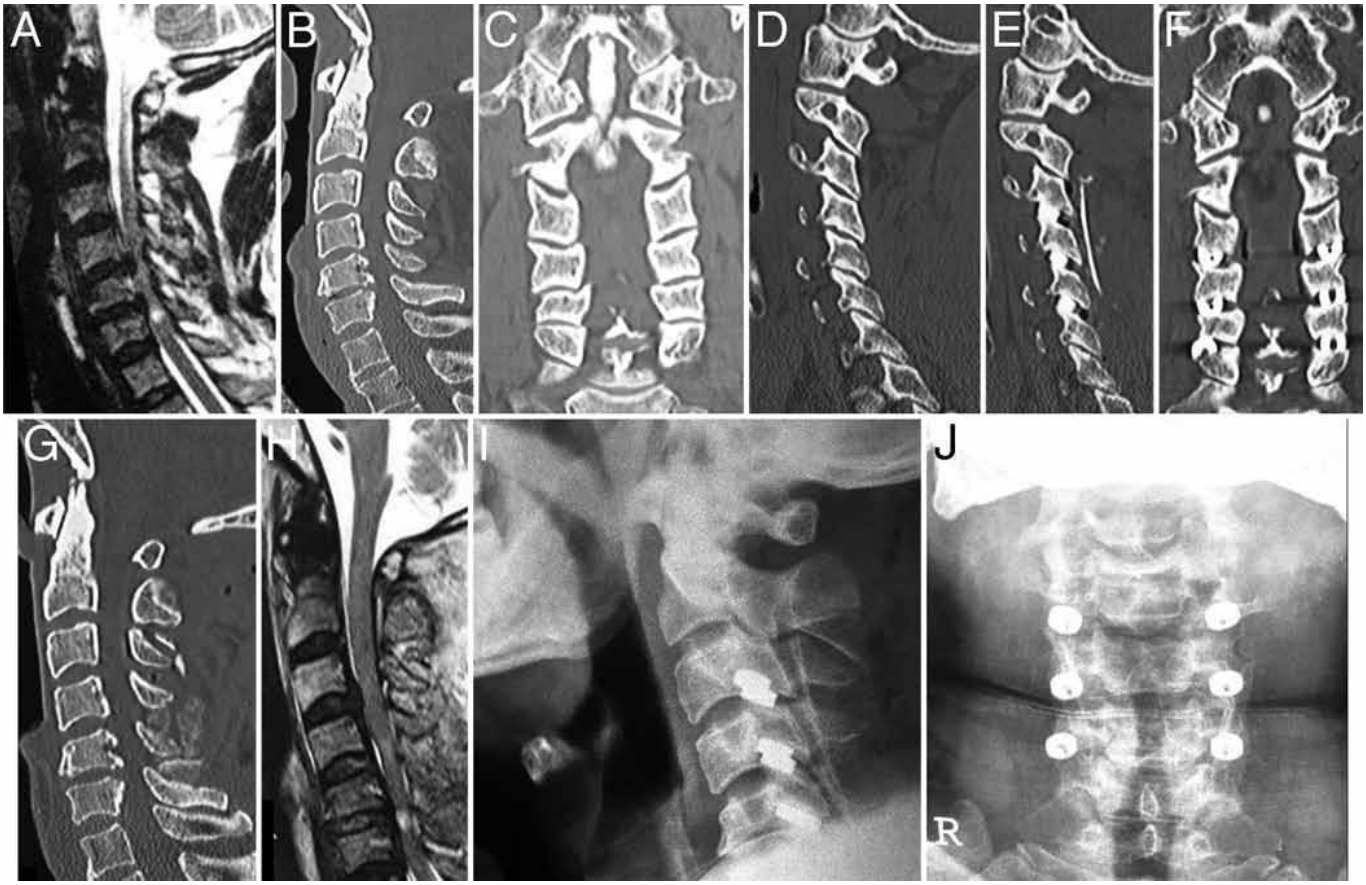


**Fig. 4.** Images obtained in a 60-year-old woman. **A–D:** Preoperative images. Sagittal T2-weighted MR image showing evidence of significant spondylotic disease **(A)**. Further MR imaging sections showed cord compression opposite C3–4, C4–5, and C5–6 disc spaces. Sagittal CT scan showing degenerative changes in the spine **(B)**. Coronal section showing the facets of the cervical spine **(C)**. Sagittal section showing the facets **(D)**. **E–J:** Postoperative images. Sagittal section through the facets showing the spacers with the C3–4, C4–5, and C5–6 facet joint **(E)**. Coronal view showing the spacers within the joints **(F)**. Note the extent of distraction achieved by the procedure. Sagittal CT scan showing distraction and increase in the intervertebral and interspinous process spaces **(G)**. Sagittal MR image showing reduction in the extent of cord compression **(H)**. Reduction in the buckling of PLL and ligamentum flavum at the levels treated can be seen. Lateral radiograph showing the spacers **(I)**. Anteroposterior radiograph showing the spacers **(J)**.

Various sizes of the spacers are available to suit the circumstances at the time of implantation. The spacer impactor holds the spacer firmly because of its screw-thread design. The base of the impactor has a flat space for impaction with gentle hammering. The spacer is impacted after wide removal of the articular cartilage. Such a wide cartilage removal assists in making an otherwise smooth and slippery surface rough for firm fixation of the implant and provides an enhanced opportunity for bone fusion. The spacer holder prevents over-insertion of the implant. The inferior edge of the transverse process of the rostral vertebra provides a natural anterior barrier and blocks the movement of the spacer beyond the confines of the facet, avoiding injury to the root and vertebral artery.

Impaction of the spacers within the facet joint of the subaxial spine simulates to an extent the joint jamming technique that we have described for atlantoaxial fixation.[8] Although intervertebral lateral mass plate and screw fixation can be done simultaneously, such a procedure was not necessary as the inherent tensile strength of the ligaments resulted in stability and fixation. We also found that 2 facet joint spacers were stronger and firmer than a single intervertebral body spacer. Biomechanical studies on the subject are in progress. The mineral density of the bones of the facets and pedicles is significantly superior to that of any other part of the vertebra, imparting greater strength to the process of fixation. The facet spacers avoided the need for neck dissection and even the need for direct manipulation and resection of the posterior osteophytes or PLL. Essentially, the decompression was achieved without removal of any part of the disc, bone, or soft tissues. The other advantage is that the technique can be performed by percutaneous and endoscopic methods. Although patients with extruded disc prolapse were not treated, it may be possible that even such patients can benefit from the increase in the spinal and root canal dimensions. Clear evidence of segmental bone fusion was a contraindication for attempting facet distraction. Investigations showed some degree of loss of lordosis, particularly in cases in which more than single-level treatment was done. However, because of the relatively small number of cases evaluated, it was not possible to

**TABLE 6: Measurement of the cervical lordotic angle**

| Degrees | No. of Patients | |
|---|---|---|
| | Preop | Postop |
| 20–35 | 4 | 6 |
| 35–45 | 8 | 14 |
| 45–55 | 16 | 12 |
| 55–65 | 8 | 4 |

conclusively identify the degree of loss of lordosis and/or reduction of neck movements. Moreover, a number of patients in the series had hyperlordosis based on the described parameters prior to surgery, which reduced to normal range after treatment. None of the patients developed any degree of kyphosis following surgery.

Distraction of the spinous processes of the vertebrae has been identified to result in reduction of spinal canal stenosis. For such a procedure, spinous process distractors are becoming increasingly popular, particularly in the lumbar spine.[16,23,25,30] Intervertebral body distractors are also commonly used after disc material resection or corpectomy.[27] Our technique results in simultaneous distraction of the spinous processes and vertebral bodies. The mean increase in the interspinous distance was 2 mm, and the increase in the intervertebral body distance ranged from 0.4 to 1.2 mm. Although firmly fixing spinous process holders and intervertebral body distractors are currently available, it was evident from our experience that intrafacet joint spacers were significantly easier to implant and stabilize. Extension of the levels of fixation was relatively easy and remarkably quick. In contrast to other available midline fixation methods, the fixation is at the fulcrum of all cervical spine movements. This is probably the reason that the stability imparted by such a spacer appears to be significantly more than the stability provided when implants are applied in other regions of the cervical vertebra. Moreover, it appeared that because of the direction of the bone profile, the interspinous distraction probably resulted in further decrease in the intervertebral disc space height compared with facet joint spacers that resulted in an increase in the disc space height. Although movement-preserving techniques are gaining acceptance, our technique involves fusion of the region. No adjacent-level disc disease was encountered in our series. However, it is clear that longer follow-up in a larger number of cases will be necessary to evaluate this feature.

The efficacy and safety of the technique are apparent from our successful results. The technique resulted in demonstrated improvements in gait, strength, sensation, pain, and degree of myelopathy. The highlight of the technique is that it is simple and significantly quicker than all other methods of decompression and fixation. The procedure can be done in isolation, or it can be used as a supplement to other techniques. It can be done when other midline methods of fixation/decompression have failed. The implant is relatively small, and the use of large metal implants extending over multiple levels, which are used in some described stabilization techniques, can be avoided. We did not observe recurrent disease, pseudarthrosis, hardware failure, or migration in any case. There were no wound infections or host rejections of the instrumentation. As the nature of implant and the material used is rather straightforward, the hardware cost can be significantly less than the implants currently in commercial use. The drawback of this study is that we did not include a comparative cohort of patients who had undergone either a traditional open anterior/posterior surgery or other minimally invasive techniques. Moreover, the exact inclusion/exclusion criteria for deployment of the technique will need to be assessed, evaluated, and determined on the basis of further experience.

We theorize that stabilization of the cervical spine with facetal spacers would obviate the disadvantages of anterior decompression, prevent the development of kyphotic deformity frequently seen after uninstrumented laminectomy, decompress the spinal cord, and produce neurological results equal or superior to those achieved by conventional and accepted methods of multilevel anterior and posterior procedures.

## Conclusions

From our experience, we conclude that intraarticular spacers can be effectively used in the treatment of cervical spondylotic radiculopathy and myelopathy. The concept is based on the understanding that degenerative spinal disorder is secondary to instability related to muscular weakness, rather than age-related reduction in the intervertebral disc "water" content. Joint distraction using spacers can be a stand-alone method of treatment, or it can be used in combination with other fixation methods and provides a critical increase in space for the spinal cord and nerve roots and a firm stabilization in such cases.

We believe that the proposed technique is a safe, effective, and rational alternative to all conventional forms of treatment for patients with single- or multilevel cervical spondylotic disease. There is certainly scope for further improvement in the type of implant and techniques of their deployment.

### Disclosure

The implants used for the study are proprietary items of Gesco India Limited Company, Chennai. The patent for the product is pending. The implant is not yet commercially available.

Author contributions to the study and manuscript preparation include the following. Conception and design: Goel. Acquisition of data: both authors. Analysis and interpretation of data: both authors. Drafting the article: Goel. Critically revising the article: both authors. Reviewed final version of the manuscript and approved it for submission: both authors. Administrative/technical/material support: both authors. Study supervision: Goel.

### References

1. Abdullah KG, Steinmetz MP, Mroz TE: Morphometric and volumetric analysis of the lateral masses of the lower cervical spine. **Spine (Phila Pa 1976) 34:**1476–1479, 2009
2. Barrey C, Mertens P, Jund J, Cotton F, Perrin G: Quantitative anatomic evaluation of cervical lateral mass fixation with a comparison of the Roy-Camille and the Magerl screw techniques. **Spine (Phila Pa 1976) 30:**E140–E147, 2005
3. Boden SD, Balderston RA, Heller JG, Hanley EN Jr, Zigler JE:

An AOA critical issue. Disc replacements: this time will we really cure low-back and neck pain? **J Bone Joint Surg Am 86:**411–422, 2004
4. Cardoso MJ, Rosner MK: Multilevel cervical arthroplasty with artificial disc replacement. **Neurosurg Focus 28(5):**E19, 2010
5. Cloward RB: The anterior approach for removal of ruptured cervical disks. **J Neurosurg 15:**602–617, 1958
6. Faldini C, Leonetti D, Nanni M, Di Martino A, Denaro L, Denaro V, et al: Cervical disc herniation and cervical spondylosis surgically treated by Cloward procedure: a 10-year-minimum follow-up study. **J Orthop Traumatol 11:**99–103, 2010
7. Fujiwara A, Kobayashi N, Saiki K, Kitagawa T, Tamai K, Saotome K: Association of the Japanese Orthopaedic Association score with the Oswestry Disability Index, Roland-Morris Disability Questionnaire, and short-form 36. **Spine (Phila Pa 1976) 28:**1601–1607, 2003
8. Goel A: Atlantoaxial joint jamming as a treatment for atlantoaxial dislocation: a preliminary report. Technical note. **J Neurosurg Spine 7:**90–94, 2007
9. Goel A: Treatment of basilar invagination by atlantoaxial joint distraction and direct lateral mass fixation. **J Neurosurg Spine 1:**281–286, 2004
10. Goel A, Desai KI, Muzumdar DP: Atlantoaxial fixation using plate and screw method: a report of 160 treated patients. **Neurosurgery 51:**1351–1357, 2002
11. Goel A, Laheri VK: Plate and screw fixation for atlanto-axial subluxation. (Technical report). **Acta Neurochir (Wien) 129:**47–53, 1994
12. Goel A, Shah A: Atlantoaxial joint distraction as a treatment for basilar invagination: a report of an experience with 11 cases. **Neurol India 56:**144–150, 2008
13. Goel A, Shah A, Gupta SR: Craniovertebral instability due to degenerative osteoarthritis of the atlantoaxial joints: analysis of the management of 108 cases. Clinical article. **J Neurosurg Spine 12:**592–601, 2010
14. Horn EM, Theodore N, Crawford NR, Bambakidis NC, Sonntag VK: Transfacet screw placement for posterior fixation of C-7. Technical note. **J Neurosurg Spine 9:**200–206, 2008
15. Huskisson EC: Measurement of pain. **J Rheumatol 9:**768–769, 1982
16. Kuchta J, Sobottke R, Eysel P, Simons P: Two-year results of interspinous spacer (X-Stop) implantation in 175 patients with neurologic intermittent claudication due to lumbar spinal stenosis. **Eur Spine J 18:**823–829, 2009
17. Lafuente J, Casey AT, Petzold A, Brew S: The Bryan cervical disc prosthesis as an alternative to arthrodesis in the treatment of cervical spondylosis: 46 consecutive cases. **J Bone Joint Surg Br 87:**508–512, 2005
18. Lied B, Roenning PA, Sundseth J, Helseth E: Anterior cervical discectomy with fusion in patients with cervical disc degeneration: a prospective outcome study of 258 patients (181 fused with autologous bone graft and 77 fused with a PEEK cage). **BMC Surg 10:**10, 2010
19. Lin EL, Wang JC: Total disk arthroplasty. **J Am Acad Orthop Surg 14:**705–714, 2006
20. Narotam PK, Pauley SM, McGinn GJ: Titanium mesh cages for cervical spine stabilization after corpectomy: a clinical and radiological study. **J Neurosurg 99 (2 Suppl):**172–180, 2003
21. Odom GL, Finney W, Woodhall B: Cervical disk lesions. **J Am Med Assoc 166:**23–28, 1958
22. Pal GP, Routal RV, Saggu SK: The orientation of the articular facets of the zygapophyseal joints at the cervical and upper thoracic region. **J Anat 198:**431–441, 2001
23. Richards JC, Majumdar S, Lindsey DP, Beaupré GS, Yerby SA: The treatment mechanism of an interspinous process implant for lumbar neurogenic intermittent claudication. **Spine (Phila Pa 1976) 30:**744–749, 2005
24. Robinson RA, Smith GW: Anterolateral cervical disc removal and interbody fusion for cervical disc syndrome. **Bull Johns Hopkins Hosp 96:**223–224, 1955
25. Siddiqui M, Nicol M, Karadimas E, Smith F, Wardlaw D: The positional magnetic resonance imaging changes in the lumbar spine following insertion of a novel interspinous process distraction device. **Spine (Phila Pa 1976) 30:**2677–2682, 2005
26. Stemper BD, Marawar SV, Yoganandan N, Shender BS, Rao RD: Quantitative anatomy of subaxial cervical lateral mass: an analysis of safe screw lengths for Roy-Camille and Magerl techniques. **Spine (Phila Pa 1976) 33:**893–897, 2008
27. Woiciechowsky C: Distractable vertebral cages for reconstruction after cervical corpectomy. **Spine (Phila Pa 1976) 30:** 1736–1741, 2005
28. Yochum TR, Rowe LJ: **Essentials of Skeletal Radiology, ed 2.** Baltimore: Lippincott Williams & Wilkins, 1996, pp 153–155
29. Yoon DH, Yi S, Shin HC, Kim KN, Kim SH: Clinical and radiological results following cervical arthroplasty. **Acta Neurochir (Wien) 148:**943–950, 2006
30. Zucherman JF, Hsu KY, Hartjen CA, Mehalic TF, Implicito DA, Martin MJ, et al: A prospective randomized multi-center study for the treatment of lumbar spinal stenosis with the X STOP interspinous implant: 1-year results. **Eur Spine J 13:** 22–31, 2004

Manuscript submitted August 23, 2010.
Accepted February 8, 2011.
Please include this information when citing this paper: published online March 18, 2011; DOI: 10.3171/2011.2.SPINE10601.
*Address correspondence to:* Atul Goel, M.Ch., Department of Neurosurgery, K.E.M. Hospital and Seth G.S. Medical College, Parel, Mumbai 400012, India. email: atulgoel62@hotmail.com.