J Neurosurg 112:1341–1346, 2010

Fluid-fluid level in pituitary tumors: analysis of management of 106 cases

Clinical article

Atul Goel, M.Ch.,[1] Abhidha Shah, M.S., M.Ch,[1] Sukhdeep Singh Jhawar, M.S., M.Ch.,[1] and Naina K. Goel, M.D.[2]

Departments of [1]Neurosurgery and [2]Neuropathology, K.E.M. Hospital and Seth G.S. Medical College, Parel, Mumbai, India

Object. The management issues of 106 cases of pituitary tumors with a fluid level within the fluid content of the cystic part of the tumor (a "fluid-fluid" level) were reviewed.

Methods. Between 2000 and March 2009, 1660 pituitary tumors were treated neurosurgically at K.E.M. Hospital. Investigations of 106 of these cases revealed a fluid-fluid level within the tumor. All patients underwent surgery via a transsphenoidal route. The mean follow-up duration was 46 months.

Results. The tumors varied in size: 31 were between 1 and 3 cm, and 75 were larger than 3 cm in maximum dimension (mean maximum dimension 3.4 cm). Fifty-two tumors had 1 fluid level, 11 had 2, and 43 had multiple fluid levels (≥ 3). The onset of symptoms was acute in 8 cases and insidious in 98 cases. In 16 cases, there was evidence of acute exacerbation of symptoms during the course of symptom progression. The symptoms were progressive in all cases. Ninety-seven percent of patients had visual deficits at the time of presentation. The solid portion of the tumor was relatively friable and vascular in most cases, and the fluid varied in color and in consistency, from a thin yellow to dark red liquid. Visual outcome was extremely gratifying in the majority of cases; of those presenting with visual dysfunction, 94% reported visual recovery in the immediate postoperative period. During the follow-up period, there was tumor recurrence in 21 cases; in 12 of these cases, the authors documented a fluid-fluid level. The histological features did not indicate malignancy in any case.

Conclusions. A fluid level within a fluid cavity in pituitary tumors is rarely reported but is not uncommon in large/giant tumors. The presence of such a feature suggests that surgery in these cases can be relatively straightforward despite the lesion's large size, and the visual outcome is gratifying. However, recurrence rates are relatively higher in such cases than in other pituitary tumors. *(DOI: 10.3171/2009.11.JNS091083)*

Key Words • **fluid-fluid level** • **pituitary apoplexy** • **pituitary tumor** • **transsphenoidal surgery**

A fluid level within a cystic fluid cavity ("fluid-fluid" level) has been recorded in a number of brain tumors and nonneoplastic lesions.[1,4–6] There are only isolated reports mentioning the presence of this feature in pituitary tumors.[2,3] Our literature survey did not reveal any clinical series focusing on the management of such pituitary tumors. We report our experience in the management of 106 pituitary tumors with fluid-fluid levels and analyze patients' immediate postsurgery and long-term clinical outcome.

Methods

Between 2000 and March 2009, 1660 pituitary tumors were surgically treated in the department of neurosurgery at K.E.M. Hospital in Mumbai. Of these, 106 tumors had clear radiological evidence of a fluid-fluid level within the confines of the tumor (Figs. 1–7). All investigations and case records were available for review. The video recording of operations in 68 cases were studied.

Classification of the Tumors

The tumors were graded according to the classification described by us earlier for giant pituitary tumors that measured at least 4 cm in their maximum transverse dimension.[2] Grade I pituitary tumors were those that were located within the sella, remained beneath the superiorly elevated diaphragma sellae, and did not invade the cavernous sinus (Figs. 1, 2, 6, and 7); Grade II were those in which the lesion invaded the cavernous sinus (Fig. 3); Grade III were those giant pituitary tumors in which the lesion invaded the cavernous sinus and in which the roof of the cavernous sinus was elevated superiorly (Fig. 4); and Grade IV pituitary tumors were those that crossed

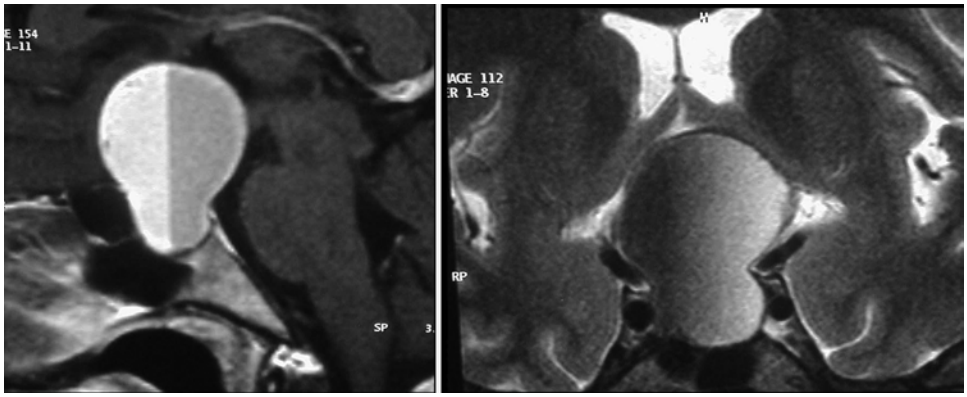

Fig. 1. ***Left:*** A T1-weighted MR image showing a Grade I pituitary tumor and a fluid level bisecting it into 2 parts. ***Right:*** Coronal T2-weighted MR image revealing layering pattern of fluid intensities.

the diaphragma sella boundary and entered into the subarachnoid spaces of the brain (Fig. 5). These tumors encased the arteries of the circle of Willis. In the present study even smaller tumors were graded according to this classification.

Results

The clinical and radiological characteristics of these tumors are shown in Tables 1 and 2. Fifty-two tumors had a single fluid level (Figs. 1, 6, and 7), 11 had 2 fluid levels (Fig. 2), and 43 had multiple fluid levels (≥ 3) (Figs. 3 and 5). In 98 cases the tumor was "nonfunctional," in 6 cases there was growth hormone dysfunction, and in 2 cases there was Cushing disease. In the subgroup of nonfunctioning pituitary tumors, we observed biochemical evidence of hypopituitarism in 38 patients. Of these, 30 patients had some degree of hypothyroidism, 20 patients had moderate hypocortisolemia, and 24 patients had mild to moderate hyperprolactinemia. In all patients surgery was performed via a sublabial transsphenoidal surgical route, using a microscope. An endoscope was not used. The solid portion of the tumors was generally soft, friable, and vascular, and the presence of a fluid-containing cyst assisted in quick and relatively easy decompression and tumor resection. In at least 38 cases the fluid was released as a gush during surgery. The fluid varied in consistency from thin xanthochromic fluid to dark red and thick liquid resembling old clotted blood. Radical surgery with the aim of resecting the entire tumor was attempted in all cases. Postoperative imaging confirmed gross-total tumor resection in 61 cases; in the remaining cases at least a small residual portion was documented. Vision improved in the immediate postoperative period in 97 patients.

After surgery, there was clinical reversal of acromegalic and cushingoid features in all patients presenting with these symptoms. During the follow-up period, however, 3 of the 6 patients with acromegaly needed subsequent irradiation for a persistently functioning residual tumor. In 1 of the 2 patients with Cushing disease, the disorder was considered to be cured when investigated using standard biochemical criteria. The other patients with Cushing disease underwent reoperation within 1 year of surgery and subsequently underwent radiotherapy for symptom and tumor recurrence. The issue of postoperative hormonal assessment in patients with nonfunctioning pituitary tumors was inconsistent and could not be evaluated to conclusion.

There were no postoperative deaths. There was no histological evidence of malignancy in any of the cases. The follow-up period ranged from 5 to 100 months (mean 46 months). In 21 cases, there was symptomatic tumor recurrence. There were 6 recurrences in cases of Grade I pituitary tumors, 9 recurrences in Grade II lesions, 5 recurrences in Grade III lesions, and 1 recurrence in Grade IV lesions. In 12 cases, the recurrent tumor also had a fluid-fluid level (Fig. 7). Postoperative radiation treatment was administered to 13 patients with significant residual tumor following surgery. All patients in whom tumors recurred and in whom reoperation was performed underwent radiation therapy.

Discussion

In a relatively short period of time and in a moderate-sized series, the number of cases of pituitary tumors with a fluid-fluid level encountered by us suggests that this en-

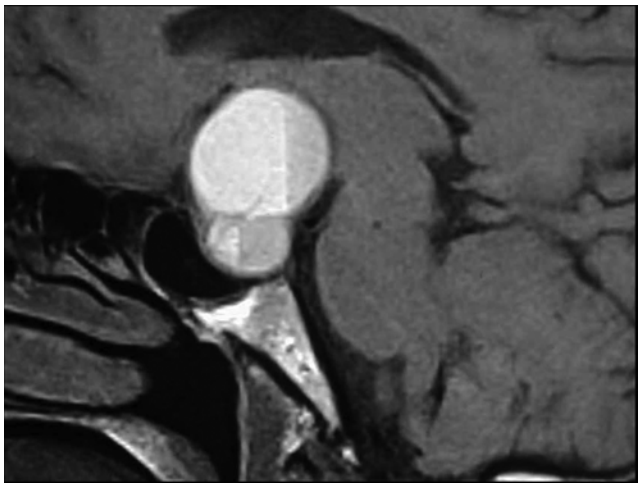

Fig. 2. A T1-weighted MR image demonstrating Grade I tumor with 2 fluid levels, 1 within its sellar component and 1 in the suprasellar component.

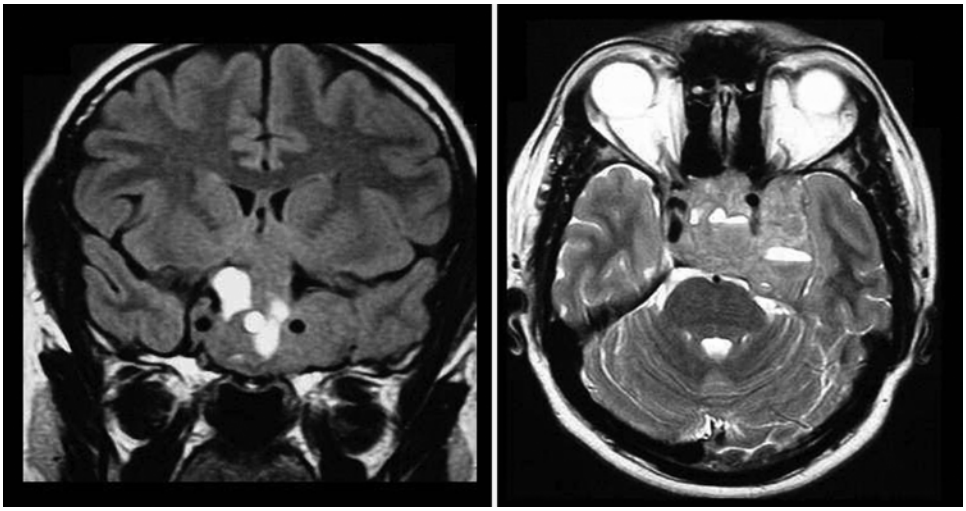

Fig. 3. ***Left:*** Coronal T2-weighted MR image showing the Grade II tumor. The tumor has areas of hyperintensity within its confines. ***Right:*** Axial T2-weighted MR image revealing fluid levels within the sellar and cavernous sinus parts of the tumor.

tity is not uncommon and is underreported and underanalyzed in the neurosurgical literature.

Fluid-fluid levels have been associated with a variety of brain, bone, and systemic neoplastic and nonneoplastic lesions.[1,5–8] A number of intracranial tumors, including pituitary tumors, have been identified to have fluid-fluid levels.[2,3] If performed in a gravity-dependent plane, CT and MR imaging depict fluid-fluid levels by virtue of contrast resolution.[8] A number of hypotheses have been proposed to explain the presence of such a physical characteristic of the tumor and layering of fluid content. Fluid-fluid levels in cystic spaces are caused by varying densities of the cyst contents. The differing viscosity/protein content of the cyst fluid contributes to the differential sedimentation.[1]

The MR imaging findings and the imaging characteristics of the tumors are elaborated in Table 2. In general, the cyst can be better visualized on T2-weighted images. Although it could not be confirmed, we believe that a reasonable impression of the nature of cyst fluid could be made based on the signal intensities of the cyst contents and on intraoperative observations. Based on our analysis, we found that the fluid-fluid level in pituitary tumors may be of 2 types: one related to intratumoral bleeding and the other related to the tumor's cystic-necrotic degeneration. Although other clinical features matched, it did appear from the analysis that pituitary tumors with a fluid-fluid level were more frequently seen in younger patients. Approximately 80% of patients in our series were younger than 40 years of age.

Among benign intracranial tumors, bleeding within a pituitary tumor is most frequently observed.[9] A number of possible causes for such bleeding have been enumerated in the literature. Intratumoral bleeding and liquefaction of the blood clot in varying stages of sedimentation appeared to be the most probable cause of such a physical formation. In 14 cases, we found evidence of multiple-level layering of the cyst content (Fig. 1 *right*). Radiological findings and intraoperative observations suggested that bleeding could have been the cause of the fluid-fluid level in approximately 57% of cases. As the nature and consistency of cyst contents varied remarkably, the cysts could not be clearly subclassified depending on the possible pathogenesis to evaluate the differences in functional

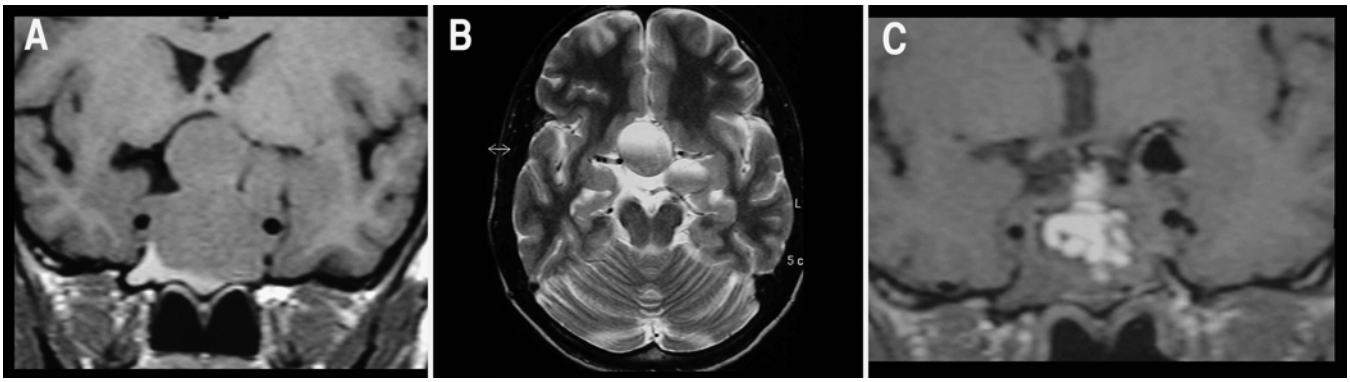

Fig. 4. Magnetic resonance imaging studies. **A:** A T1-weighted image showing a Grade III pituitary tumor. Two definite fluid levels are seen. **B:** A T2-weighted MR image demonstrating fluid levels within the sella and within the cavernous sinus roof portion of the tumor. **C:** Postoperative T1-weighted scan showing resection of the tumor. Fat within the sella and air under the superiorly elevated roof of the cavernous sinus can be seen.

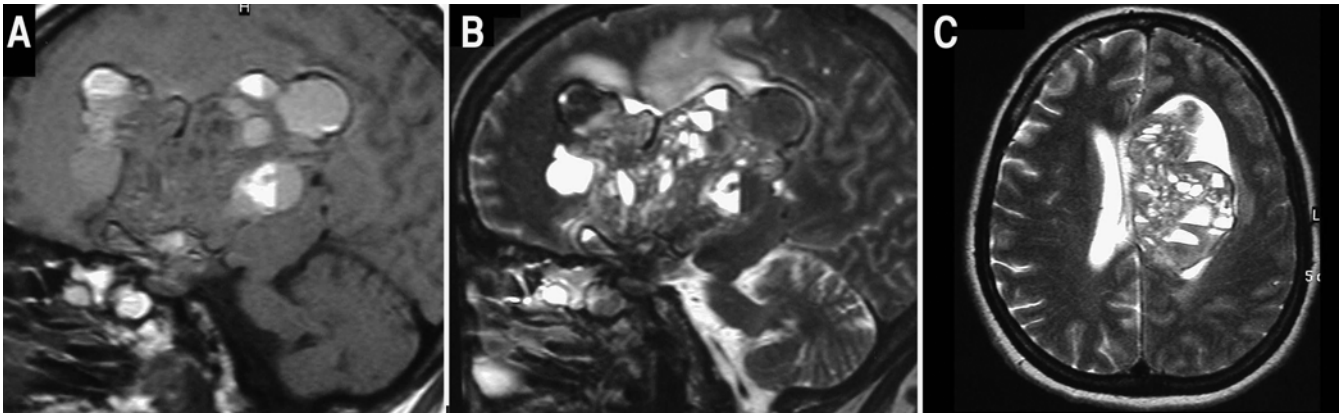

Fig. 5. Magnetic resonance imaging studies. **A:** Preoperative T1-weighted image of a giant pituitary tumor revealing multiple fluid-fluid levels. **B:** Preoperative T2-weighted image showing the tumor and the multiple fluid-fluid levels. **C:** Axial T2-weighted MR image demonstrating the multiple fluid-fluid levels.

outcome after surgery. The tumor adjoining the cyst was hypervascular, when compared with the general vascularity of pituitary tumors, which may also be the cause of its increased propensity to bleed. Although bleeding within the confines of the tumor—as well as subsequent resorption of the clot—appears to be the most probable cause for the fluid-fluid level, there are several features that undercut this theory. The progressive nature of symptoms suggests that the bleeding episode may have an "apoplectic" proportion only in a small minority of cases. None of the patients in the present series had a classic pituitary apoplexy–like presenting clinical feature and none of the patients had any clinical evidence of spontaneous symptom resolution. The sella was large in all cases, suggesting the chronicity of the tumor growth process, as against an acute nature of pituitary apoplexy, where the sella may or may not be large. Multiple cysts with fluid-fluid levels were identified in 41% of cases. Of these, except in 5 cases, the signal intensities in each of the cysts were almost similar. This feature suggests that bleeding may not be the sole cause, as simultaneous bleeding at multiple areas may not be possible. However, in cases involving multiple cysts, some of the cysts did exhibit evidence of hemorrhage. Patients' remarkable recovery of vision in the postoperative period also suggests that the fluid-fluid level in pituitary tumors formed a "pressure cyst" that probably grew over time, in contrast to a resolving clot that progressively decreases in size and is essentially of low pressure. Moreover, an acute bleeding episode is a neurally destructive phenomenon, and visual recovery is spontaneous and may not be as dramatic following surgery. Although parallel assessments were not possible, it was clear from our observations that the rapidity and extent of visual recovery in cases of pituitary tumors with a fluid-fluid level was much more significant compared to those tumors in which this physical characteristic was absent. None of the patients had gross or manifest hypopituitarism, either at the time of presentation or even in the postoperative phase. This feature also suggested the gradual progressive nature of compression of the normal gland. Microhemorrhages in the cyst or subclinical bleeding occurring over a period of time may explain the presence of blood and the progressive nature of clinical symptoms and anatomical reformation of the region.

In cases of tumor liquefactive necrosis and cystic degeneration in several benign and malignant tumors, a fluid level in the cyst cavity has been recorded. In necrotic tumors, the fluid filling the cavity early on is more proteinaceous than newer interstitial fluid.[1] The sizes of the tumors in our series were remarkably large compared with those in most other series. In 71% of our cases the tumors were larger than 3 cm in their largest dimension

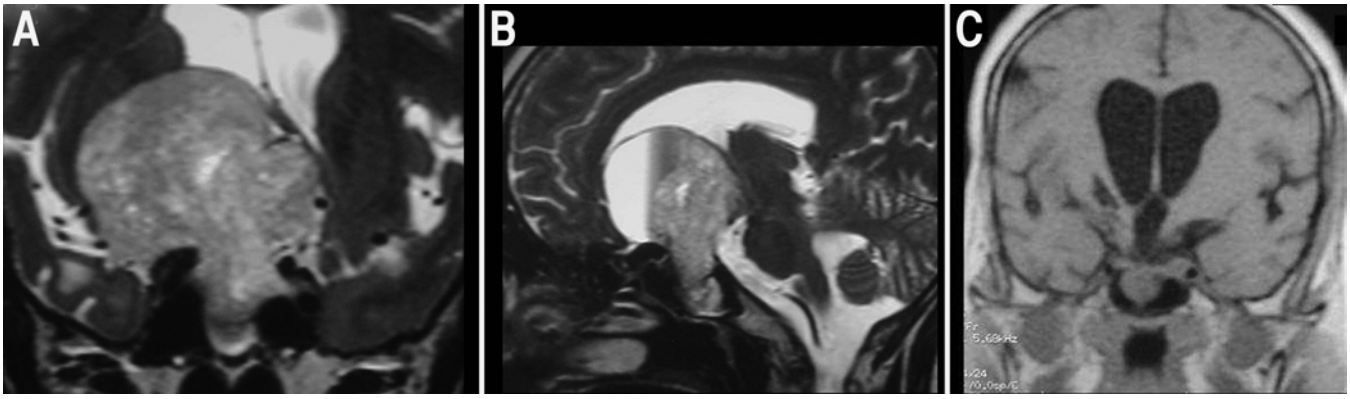

Fig. 6. Magnetic resonance imaging studies. **A:** Coronal T2-weighted image revealing a Grade I giant pituitary tumor. **B:** Sagittal image showing a fluid-fluid level in the anterior part of the tumor. **C:** Image obtained after resection of the tumor.

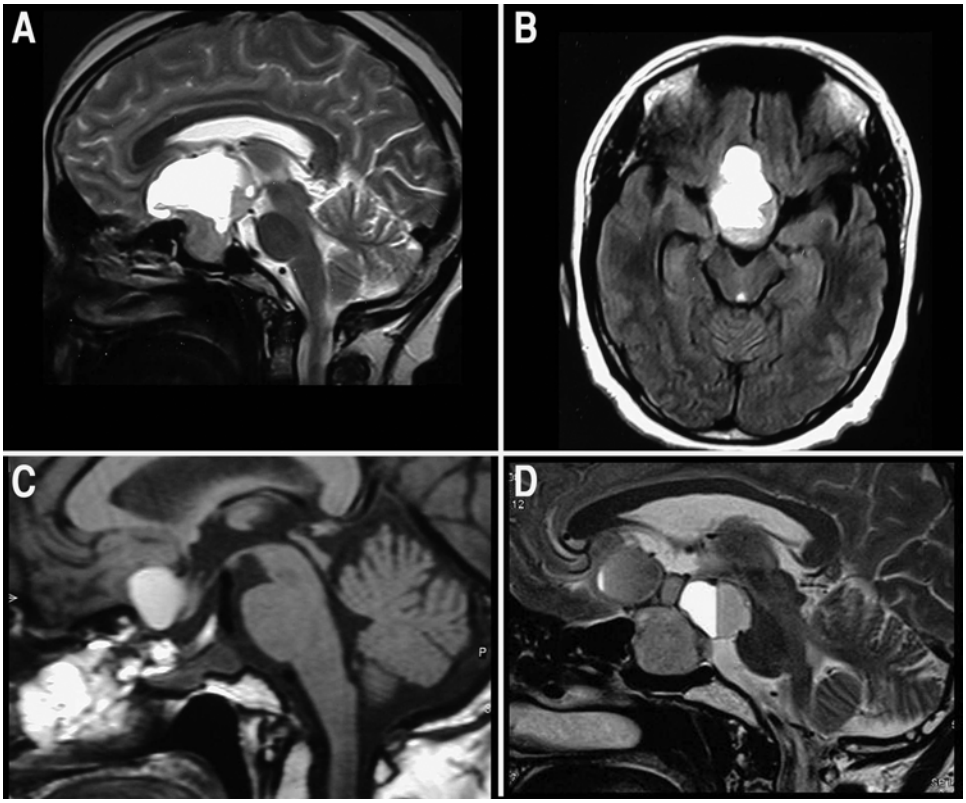

Fig. 7. Magnetic resonance imaging studies. **A:** Sagittal T2-weighted image of a Grade I pituitary tumor showing a fluid-fluid level. **B:** A T1-weighted image demonstrating a fluid-fluid level. **C:** Postoperative image demonstrating a small residual cystic tumor. **D:** A T2-weighted MR image acquired 3 years after surgery showing recurrence of the tumor that contained multiple fluid-fluid levels.

(mean size 3.4 cm). It cannot be confirmed if size was the main reason for the significantly high number of fluid-fluid levels detected in the pituitary lesions in our series. Increased size was generally seen to be associated with hypervascularity of the tumor. Cystic and necrotic degeneration and intratumoral hemorrhages are both possible in such a situation. The other remarkable feature of the tumor, in cases involving multiple cysts, was its soft consistency and features suggestive of liquefactive necrosis or cystic degeneration. In 43 cases there were several microcysts, each cyst having fluid-fluid levels. The cystic fluid material in pituitary tumors appears to have a special proteinaceous content that makes it prone to fluid-fluid levels. Unfortunately, the evaluation of the nature of fluid content was not carried out in any case.

Despite the relatively large tumor size and invasive pattern of growth, positive features in the management were present: surgery was made relatively easy because of the cyst content, and visual impairment rapidly resolved postoperatively. In general and when compared with other hormonally active pituitary tumors, it appears that hormonal outcome may not be satisfactory. However, such a conclusion cannot be made with certainty because there were relatively few hormonally active tumors in the series. Although in no case were the histological features suggestive of malignancy, a tumor recurrence rate of 20% was significantly greater than the overall recurrence rate of less than 7% in our series. In 12 cases, the recurrent tumor also had a fluid-fluid level. This feature does indicate a special nature of the tumor that is prone to such a physical formation. It appeared that the grade of the tumor affected the overall outcome in these cases. Patients with higher-grade tumors fared relatively poorly and the recurrence rate was higher. In 18 cases in which there was recurrence, there was a residual tumor following the first surgery, which was related to either the unusually large size of the tumor or to the invasive pattern of its growth. The tumor recurred in 7 cases despite the provision of radiation treatment.

The use of radiation therapy in pituitary tumors is the subject of debate. In general, radical resection of the tumor was carried out in our entire series; radiotherapy was advocated in selected cases and was particularly used in patients with higher-grade tumors.[2] Radiation treatment was given in all cases in which there was tumor recurrence and a need for repeat surgery. Based on our experience with radical surgery, recurrence, and postoperative radiotherapy, we believe that the issue of upfront postoperative radiation treatment in tumors with fluid-fluid levels warrants evaluation.

Disclosure

The authors report no conflict of interest concerning the materials or methods used in this study or the findings specified in this paper.

Author contributions to the study and manuscript preparation include the following. Conception and design: A Goel. Acquisition of data: A Goel, AH Shah, SS Jhawar. Analysis and interpretation

TABLE 1: Summary of clinical features in 106 patients with fluid-fluid level in pituitary tumors*

Parameter	No. of Patients	(%)
no. of patients	106	
sex		
male	56	53
female	50	47
age range (yrs)		
10–20	5	5
21–30	38	36
31–40	42	40
41–50	11	10
51–60	8	7
61–70	2	2
onset of symptoms		
acute	8	7
progressive	98	93
hormonal abnormalities		
nonfunctioning	98	93
GH-secreting	6	5
ACTH-secreting	2	2
visual deficit grade		
I	54	55
II	26	26
III	15	16
IV	3	3

* ACTH = adrenocorticotropic hormone; GH = growth hormone.

TABLE 2: Summary of radiological and physical characteristics

Radiological Parameter	No. of Patients	(%)
grade		
I	62	58
II	26	25
III	15	14
IV	3	3
size (cm)		
1–2	8	8
2–3	23	22
3–4	51	48
4–5	14	13
>5	10	9
no. of fluid levels		
1	52	49
2	11	10
≥3	43	41
type		
intratumoral hemorrhage	60	57
cystic degeneration	46	43
T1-weighted image of supernatant		
hyperintense	67	63
hypointense	5	5
isointense	34	32
T1-weighted image of subnatant		
hyperintense	14	13
hypointense	3	3
isointense	89	84
T2-weighted image of supernatant		
hyperintense	96	91
hypointense	7	6
isointense	3	3
T2-weighted image of subnatant		
hyperintense	11	10
hypointense	0	0
isointense	95	90

of data: A Goel, AH Shah, SS Jhawar, N Goel. Drafting the article: A Goel, AH Shah, N Goel. Critically revising the article: A Goel, N Goel. Reviewed final version of manuscript and approved it for submission: A Goel, N Goel. Study supervision: A Goel, N Goel.

References

1. Catalano P, Fang-Hui E, Som PM: Fluid-fluid levels in benign neurogenic tumors. **AJNR Am J Neuroradiol 18:**385–387, 1997
2. Goel A, Nadkarni T, Muzumdar D, Desai K, Phalke U, Sharma P: Giant pituitary tumors: a study based on surgical treatment of 118 cases. **Surg Neurol 61:**436–446, 2004
3. Lenthall RK, Dean JR, Bartlett JR, Jeffree MA: Intrapituitary fluid levels following haemorrhage: MRI appearances in 13 cases. **Neuroradiology 41:**167–170, 1999
4. Menon RK, Muzumdar D, Shah A, Goel A: Blood-fluid level in cortical venous thrombosis—a rare diagnostic entity. **Surg Neurol 71:**111–114, 2009
5. Patankar T, Prasad S, Pardiwala D, Gupta S, Goel A: Fluid-fluid levels in benign neurogenic tumours. Report of two cases and review of literature. **Rivista di Neuroradiologia 11:** 893–896, 1998
6. Prasad S, Gupta S, Patankar T, Goel A: Fluid-fluid levels in intracranial schwannomas. **Australas Radiol 43:**529–531, 1999
7. Soyer P, Bluemke DA, Fishman EK, Rymer R: Fluid-fluid levels within focal hepatic lesions: imaging appearance and etiology. **Abdom Imaging 23:**161–165, 1998
8. Tsai JC, Dalinka MK, Fallon MD, Zlatkin MB, Kressel HY: Fluid-fluid level: a nonspecific finding in tumors of bone and soft tissue. **Radiology 175:**779–782, 1990
9. Wakai S, Fukushima T, Teramoto A, Sano K: Pituitary apoplexy: its incidence and clinical significance. **J Neurosurg 55:** 187–193, 1981

Manuscript submitted July 20, 2009.
Accepted November 2, 2009.
Please include this information when citing this paper: published online December 4, 2009; DOI: 10.3171/2009.11.JNS091083.
Address correspondence to: Atul Goel, M.Ch., Department of Neurosurgery, K.E.M. Hospital and Seth G.S. Medical College, Parel, Mumbai 400012, India. email: atulgoel62@hotmail.com.