

Original Article

Fiber dissection of the visual pathways: Analysis of the relationship of optic radiations to lateral ventricle: A cadaveric study

Vikrant B. Pujari, Hiriyuki Jimbo, Nitin Dange, Abhidha Shah, Sukhdeep Singh, Atul Goel

Department of Neurosurgery, King Edward Memorial Hospital and Seth G.S. Medical College, Parel, Mumbai, India

Objective: Using a fiber-dissection technique, our aim is to study the fiber bundles of the optic radiation. We focused on the course, the length, anatomical relations with lateral ventricle and the relevance of these finding during surgery in the region. **Materials and Methods:** Five previously frozen and formalin-fixed cadaveric human brains were used. The dissection was done using the operating microscope. Fiber dissection techniques described by Klingler were adopted. The primary dissection tools were handmade, thin, and wooden and curved metallic spatulas with tips of various sizes. Lateral and inferior temporal approaches were made and the optic fiber tracts were dissected. **Results:** Resections that extend through the roof of the temporal horn more than 30 mm behind the temporal pole cross the Meyer's loop. In the middle temporal gyrus approach, resection that is taken through the lateral wall of the temporal horn more than 55-60 mm behind the temporal pole may cross the optic radiation during their course here on the lateral wall. **Conclusion:** The presented fiber dissection study clarifies the relationship of optic radiation. Such fiber dissection studies are only few in the literature.

Key words: Fiber dissection, Meyer's loop, microsurgical anatomy, optic radiation, temporal lobe

Introduction

In temporal lobe region surgery, for tumors and epilepsy, the exact anatomical relationship of the optic tract fibers to temporal horn are inadequately visualized on conventional cadaveric brain dissection. Fiber dissection of the brain delineates the anatomical details of the tracts clearly and assists in providing a 3-dimensional perspective. Only a few studies are available in the literature concentrating on fiber

dissection of the brain in general and on optic tracts in particular.^[1-5] The surgical approach to temporal horn and mediobasal structures can be categorized into three main groups: lateral, subtemporal and transsylvian.^[6] These approaches have their own merits and demerits based on location of language and visual processing areas in the lateral temporal lobe and underlying fibers including the optic radiations.

In this presentation, we attempt to evaluate the anatomical relationships of optic radiations and advantage of approach to temporal horn through safe area of lateral wall of temporal horn.

Materials and Methods

Five normal human cerebral hemispheres were fixed in formalin for forty days and then frozen at the temperature of 10-15 degrees Celsius for fourteen days. We dissected these specimens under the operating microscope (with 6X to 40X magnification) using the fiber-dissection techniques initially described by Klingler.^[7] The primary dissection tools were handmade, thin, and wooden and curved metallic spatulas with tips of various sizes. Lateral and inferior temporal approaches were made to expose the region. The inferior part of the temporal lobe and floor of temporal horn including short and long association fibers, head, part of body of hippocampus, fimbria, amygdala were removed. Fibers of optic radiation in the roof and the lateral wall of temporal horn were exposed by removing the ependymal layer. With further dissection optic radiation fibers were followed into the lateral geniculate body and to the occipital cortex. The distance between tip of Meyer's loop and temporal pole, length and breadth of the optic radiation from tip of Meyer's loop to calcarine fissure was measured.

Dr. Atul Goel

Department of Neurosurgery, K.E.M. Hospital and Seth G.S. Medical College, Parel, Mumbai-400 012, India. E-mail: atulgoel62@hotmail.com

Results

The optic radiations extended from the lateral geniculate body to the occipital cortex [Figure 1]. Anatomical relation of Meyer's loop with adjacent structures is shown in Figure 2-4. Distance from temporal pole to tip of Meyer's loop was 22 to 30 mm (average of 25 mm, [Figure 5]). The average length of the optic radiation from the tip of Meyer's loop to the calcarine fissure was 105 mm. The breadth of the optic radiation was 17 mm and it enlarged towards to occipital pole [Figure 6]. The distance from tip of Meyer's loop to the point where optic radiation curves on the lateral wall of temporal horn were identified to be 25 to 30 mm and the distance from temporal pole to this point was 55 to 60 mm. The distance between tip of Meyers loop and important landmarks in are shown in Figures 1-9.

Discussion

Visual pathways originate from temporal half of ipsilateral retina as nerve fibers of optic tract, which begins at posterolateral corner of optic chiasma, pass posterolaterally between anterior perforated substance and tuber cinereum. These fibers lie superior to medial aspect of temporal lobe on lateral aspect of crus cerebri. On the crus cerebri, the optic tract is close to the choroidal fissure of inferior horn of lateral ventricle and is crossed by the anterior choroidal branch of the internal carotid artery on its way to fissure, and by the basal vein passing around the midbrain to great cerebral vein. Each optic tract enters the corresponding lateral geniculate body appearing to divide into two roots. The medial root seems to pass to medial geniculate body, but the only fibers which continue posterior to lateral geniculate body are those of the brachium

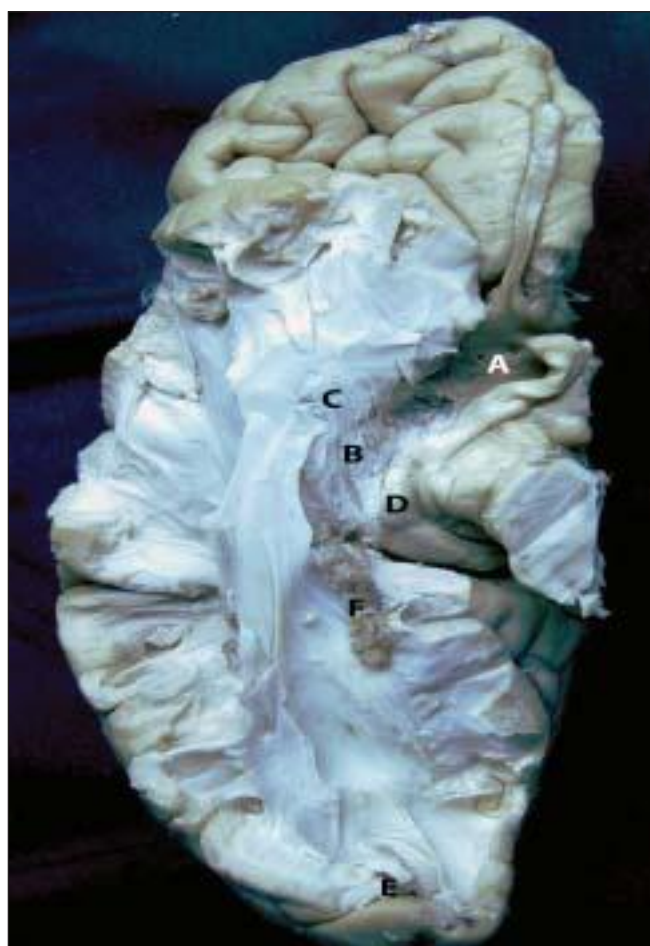

Figure 1: Anterior perforated substance (A) Inferior view of optic radiation showing fibers of optic radiation starting from lateral geniculate body goes anteriorly toward the tip of temporal horn in its roof (Meyer's loop) (B, C) Lateral geniculate body (D) and curves posteriorly to lie in lateral wall of temporal horn and atrium to reach the calcarine sulcus of occipital lobe on its medial surface (E, F).

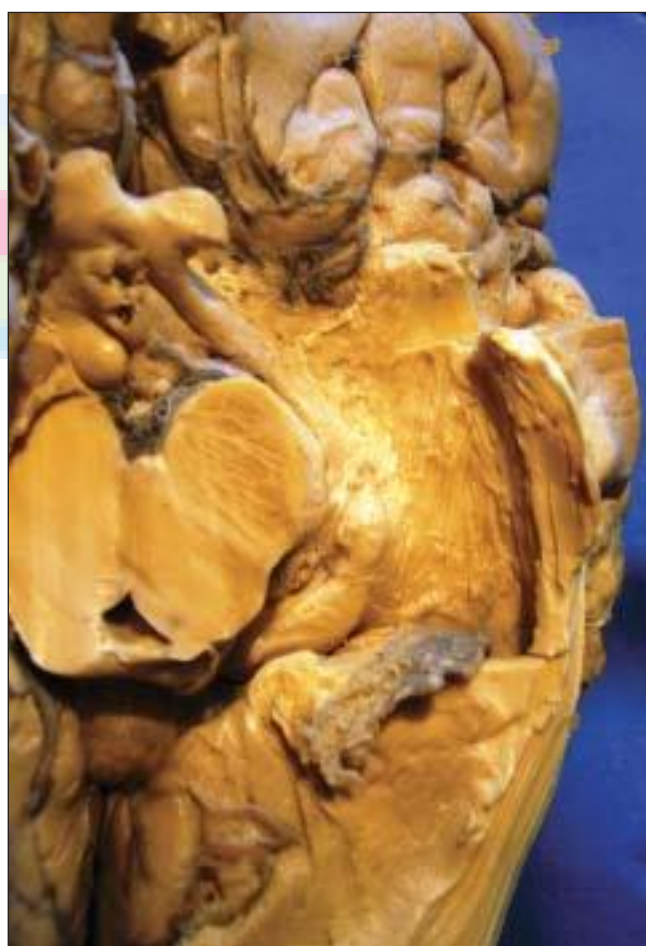

Figure 2: Inferior view of left temporal lobe, here amygdala, body of hippocampus and roof of temporal horn has been removed to view the lateral geniculate body, optic radiation, Meyer's loop, lateral wall of temporal horn, and reflected choroid plexus

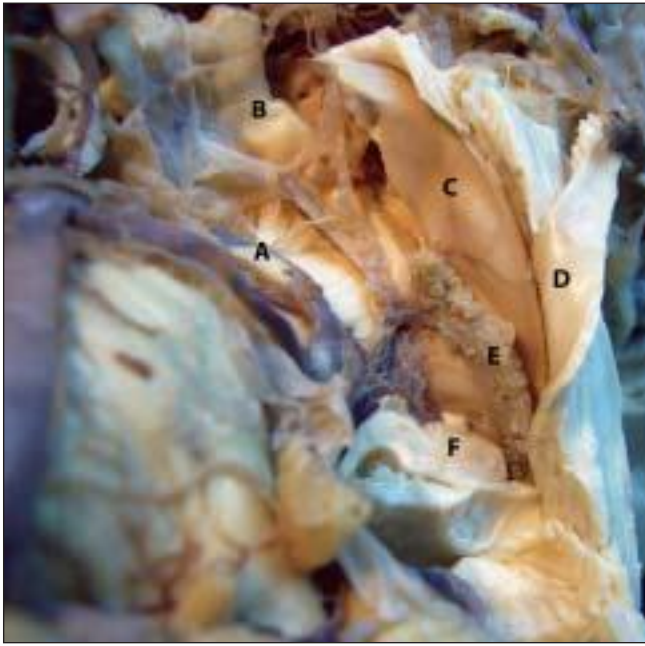

Figure 3: Inferior view of temporal horn showing anatomical relation of temporal horn. Posterior cerebral artery (A) optic tract (B) roof of temp. horn (C) Lateral wall of temp. horn (D) Choroid plexus (E) Tail of hippocampus (F)

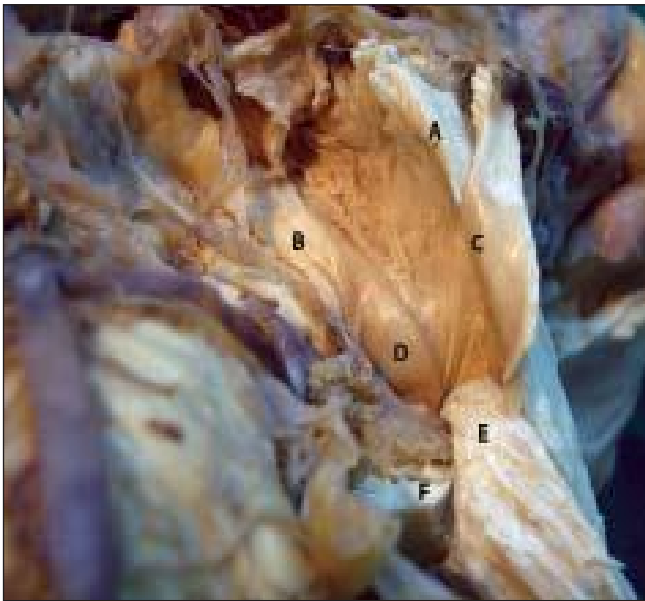

Figure 4: Inferior view of temporal horn showing Meyer's loop (A), optic tract (B), reflected roof (C), lateral geniculate body (D), lateral wall of temporal horn (E) and tail of hippocampus (F)

of the superior colliculus which run in the interval between the two roots to the superior colliculus. Each optic tract contains nerve fibers which originate from temporal half of ipsilateral retina and the nasal half of the contralateral retina.

Optic radiation starts at lateral geniculate body, proceeds posteriorly by dividing into three bundles, anterior or Meyer's loop,^[8] central bundle and posterior bundle. These fibers lie in sublenticular and

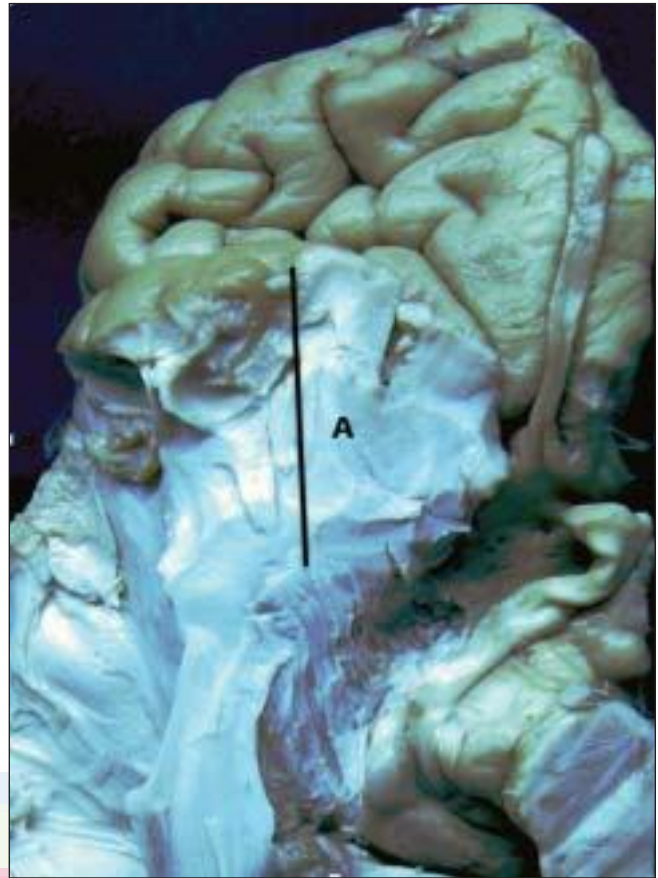


Figure 5: Inferior view of right temporal and frontal lobe showing the distance between temporal pole and tip of Meyer's loop. The distance is 22-30 mm, average is 25 mm (A)

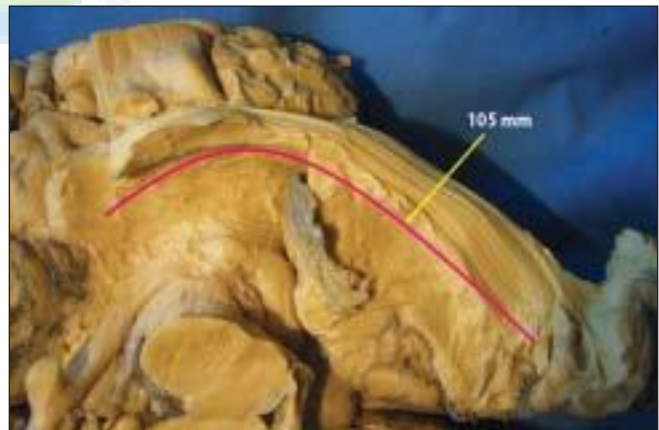


Figure 6: Inferior view of right temporal and occipital lobes showing length of optic radiation from tip of Meyer's loop to calcarine sulcus. This length is average 105 mm

retrolenticular parts of internal capsule and then curve around the temporal horn and atrium. Subsequently, these fibers are separated from ventricle surface by thin layer of tapetal fibers. Anterior bundle fibers reach at inferior lip of calcarine sulcus, center bundle fibers at occipital lobe and posterior fibers end at superior lip

of calcarine sulcus on medial surface of occipital lobe [Figure 7].

The study revealed that the distance from temporal pole to tip of Meyer's loop is average 25 mm, any resections that extend through the roof of the temporal horn more than 30mm behind the temporal pole cross

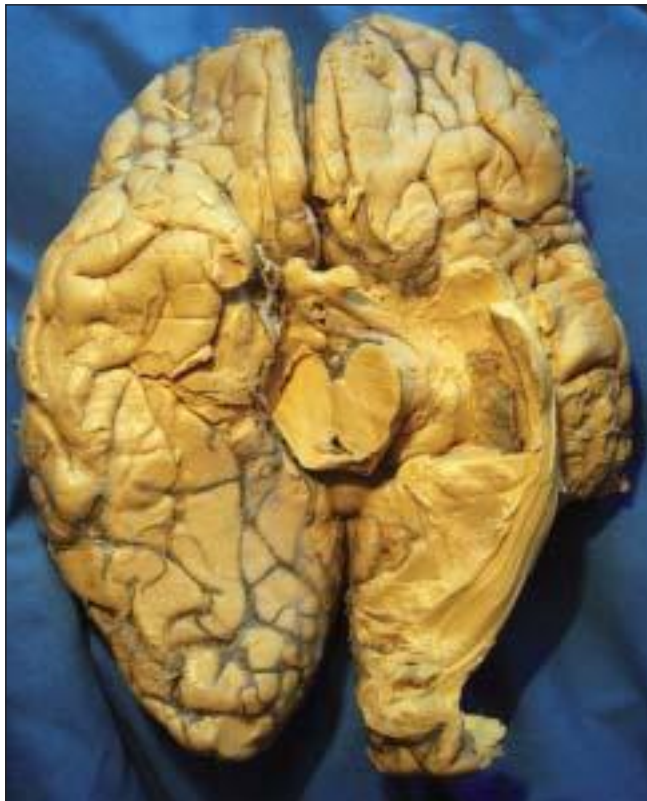

Figure 7: Optic radiation is divided into three bundles, the anterior bundle fibers reach at inferior lip of calcarine sulcus, center bundle fibers at occipital lobe and posterior bundle fibers end at superior lip of calcarine sulcus on medial surface of occipital lobe



Figure 8: Lateral view of optic radiation showing safe area of approach to the temporal horn. A safe incision is 40 mm behind the temporal pole in lateral wall of the temporal horn at this area the Meyer's fibers curved only in roof and not on the lateral wall but they come on lateral wall of temporal horn beyond 55-60 mm from the pole of temporal lobe. The circle shows area on lateral wall of temporal horn where there is no optic radiation

the Meyer's loop. The distance from temporal pole to a point where optic radiation curves on lateral wall of temporal horn is 55 to 60 mm, any resection that is taken through the lateral wall of the temporal horn more than 55-60 mm behind the temporal pole may cross the optic radiation as they curve here on lateral wall. Contralateral superior quadrantanopia has been reported to occur in approximately 50% of patients after temporal lobectomy.^[9,10,13-15]

Transtemporal and trans-sylvian approaches are commonly used for amygdala-hippocampectomy.^[11,12] Middle temporal gyrus approach to the temporal horn has a low risk of damaging the Meyer's loop if incision is made 40 mm behind the temporal pole in lateral wall of the temporal horn at this area the Meyer's fibers curved only in roof and not on the lateral wall but they come on lateral wall of temporal horn beyond 55-60 mm from the pole of temporal lobe. The circle in Figure 8 shows area on lateral wall of temporal horn where there is no optic radiation. Temporal horn can also be entered through the floor of sylvian fissure from a triangle without damaging the optic radiation. This triangle is bounded medially by optic tract, laterally by Meyer's loop, the apex is at the lateral geniculate body and base is formed by amygdaloid nucleus [Figure 9].

Radiological techniques such as MRI and reconstructed diffusion tensor fiber tractography of the optic radiation can be used preoperatively to avoid damage to optic radiation during temporal lobe surgery, because in some cases anterior fibers of Meyer's loop curve more anteriorly so that the distance between the temporal pole and tip of Meyer's loop is reduced to less than 25 mm. This fiber dissection study is beneficial to increase our knowledge of brain anatomy, which is essential for neurosurgical approaches to avoid a damage of the optic radiations.

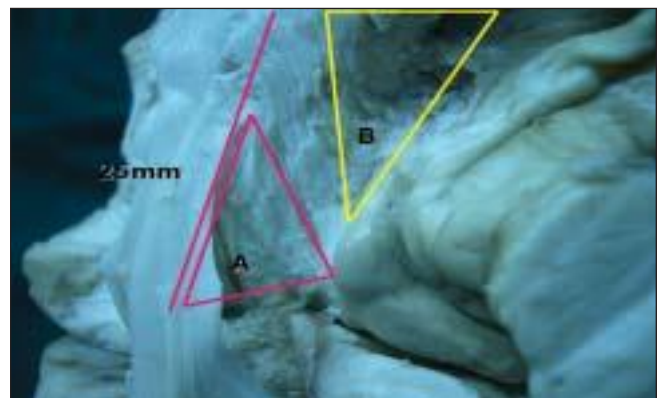


Figure 9: Safe approaches to temporal horn are middle temporal gyrus and trans-sylvian. Approaches are shown in triangles A and B respectively. Triangle A is bounded Medially by Meyer's loop, laterally by lateral wall of temporal horn, apex is formed by tip of temporal horn, base is formed by a line joining a point 55 mm behind the temporal pole and lateral geniculate body. Triangle B is bounded medially by optic tract lateral by Meyer's loop, the apex at lateral geniculate body and base is formed by amygdale.

References

1. Ebeling U, Reulen HJ. Neurosurgical topography of the optic radiation in the temporal lobe. *Acta Neurochir (Wien)* 1998;92:29-36.
2. Rasmussen AT. The extent of recurrent geniculocalcarine fibers (loop of Archambault and Meyer) as demonstrated by gross brain dissection. *Anat Rec* 1943;85:277-82.
3. Ture U, Yasargil MG, Friedman AH, Al-Mefty O. Fiber dissection technique: Lateral aspect of brain. *Neurosurgery* 2000;47:417-27.
4. Van Buren JM, Baldwin M. The architecture of the optic radiation in the temporal lobe of man. *Brain* 1958;81:2-41.
5. Williams PL, Bannister LH, Berry MM, Collins P, Dyson M, Dussek JE, et al. *Gray's Anatomy*. New York: Churchill Livingstone; 1995.
6. Sincoff EH, Tun Y, Abdulrauf SI. White matter fiber dissection of the optic radiations of the temporal lobe and implications for surgical approaches to the temporal horn. *J Neurosurg* 2004;101:739-46.
7. Ludwig E, Klinger J. *Atlas cerebri Humani*. Basel: Kager; 1956.
8. Meyer A. The connections of the occipital lobes and the presents statues of the cerebral visual affections. *Trans Assoc Phys* 1907;22:7-23.
9. Pathak-Ray V, Ray A, Walters R. Detection of visual field defects in patients after temporal lobectomy for mesial temporal sclerosis-establishing eligibility to drive. *Eye* 2002;16:744-8.
10. Egan RA, Shults WT, So N. Visual field deficits in conventional anterior temporal lobectomy versus amygdalohippocampectomy. *Neurology* 2000;55:1818-22.
11. Yoshor D, Hamilton WJ, Grossman RG. Temporal lobe operations for drug resistant epilepsy. In: Schmidek III, Roberts DW, editors. Vol 2. Philadelphia: Saunders Elsevier Inc; 2006. p. 1383-93.
12. Yasargil MG, Teddy PJ, Roth P. Selective amygdale-hippocampectomy: Operative anatomy and surgical technique. In: Krayenbuhl H, editor. *Advances and technical standards in neurosurgery*. Vol 12. New York: Springer-Verlag; 1985. p. 93-123.
13. Salanova V, Markand O, Worth R. Temporal lobe epilepsy surgery: Outcome, complications and late mortality rate in 215 patients. *Epilepsia* 2002;43:170-4.
14. Rydenhag B, Silander HC. Complications of epilepsy surgery after 654 procedures in Sweden, September 1990-1995: A multicenter study based on the Swedish National Epilepsy Surgery Register. *Neurosurgery* 2001;249:51-7.
15. Behrens E, Schramm J, Zentner J. Surgical and Neurological complications in a series of 708 epilepsy surgery procedures. *Neurosurgery* 1997;41:1-10.

Accepted on 18-04-08

Source of Support: Nil, Conflict of Interest: None declared.

